Illustrations of Dissections

IN A SERIES OF

ORIGINAL COLOURED PLATES THE SIZE OF LIFE,

REPRESENTING THE W.T. Clegg, F.R.C.S. Dr Carkinstall

DISSECTION OF THE HUMAN BODY,

WITH DESCRIPTIVE LETTER-PRESS IN DEMY OCTAVO.

BY

GEORGE VINER ELLIS,

Professor of Anatomy in University College, London;

AND

G. H. FORD, ESQ.

clear well marked early copy of 1st. edition - mounted on linen & bound in buckram. W.T.C.

£6-6. without the linen mounting, &c..

THE DRAWINGS ARE FROM NATURE AND ON STONE BY MR. FORD FROM DISSECTIONS BY PROFESSOR ELLIS.

LONDON: JAMES WALTON,

BOOKSELLER AND PUBLISHER TO UNIVERSITY COLLEGE,

137, GOWER STREET.

1867.

A. Pect. major
B. Pect. minor
C. Lat. dorsi
D. Teres major
F. Serratus magnus
H. Subscap.
K. Coraco-brachialis
L. Biceps
M. Fascia of arm
N. Triceps
P. External head of triceps

a. Axillary artery
b. Long thoracic or Ext. Mammary of Quain
d. Alar thoracic
e. An irreg. Ext. Mammary
f. Subscapular
g. Dorsal scapular
h. Post. Circumflex
n. Cut. artery with Int. Cut. of musc. Sp.
o. Art. to long head of Triceps

t. Axillary Vein
m. Subscap. Vein
p. Ext. Mammary Vein
r. Cut. & musc. Vein

1. Lat. Cut. of 2nd Intercos. nerve.
2. Offset of 3rd intercos. n.
3. " " 4th " " "
4. " " 5th " " "
5. " " 6th " " "
6 ant. Branch of 2nd Intercos. n.
+++ do of others.
7. Commun. br. to Nerve of Wrisberg from offset of 2nd intercos. n.
8. Nerve to the Teres muscle.
9. Subscap. n.
10. n. to Serratus Magnus.
11. Nerve of Wrisberg.
12. Circumflex n.
13. Musculo Spiral.
14. Offset of musculo Sp. to Triceps.
16. Int. Cut. of musc. Sp.
18. Large Int. Cut.
20 Offset of Int. Cut. to integum.
21 Ulnar nerve.
22 Median nerve.

note musc. and Cut. offsets from Musculo Spiral.

From a dissection by G. V. Ellis

A. Pect. Major.
B. Pect. Minor.
C. Lat. Dorsi.
D. Teres Major.
F. Serratus Magnus.
H. Subscapularis.
J. Clavicle.
K. Coraco-brachialis.
L. Biceps short head.
O. Biceps long head.
N. Triceps Extensor brachii.
P. Insert. of Pect. Major.
R. Deltoid.
S. Subclavius muscle.
V. Costo-coracoid membr.

a. axillary artery.
b. Supr. thoracic br.
c. Acromial thoracic br.
d. Long thoracic br.
e. Ext. mammary br.
f. Subscap. branch.
g. Dors. br. of Subscap.
h. axillary Vein.
k. brachial Vein.
l. Cephalic Vein.
m. External mammary Vein.

1. Brachial plexus.
2. thoracic offsets. Ext. ant. Thorac. 3. Int. ant. Thoracic.
5. N. to Serr. Magnus.
6. N. to Latissimus.
8. Lat. Cut. of 2nd intercos.
9. Small Int. Cut. n.
10. N. to Teres Major.
11. Musculo-Cut. n.
12. Median n.
13. Ulnar n.
14. Large Int. Cut. n.
15 Upper Short Subscap.

circumflex & musculo spiral nerves are cov. by the axillary vessels.

2

2

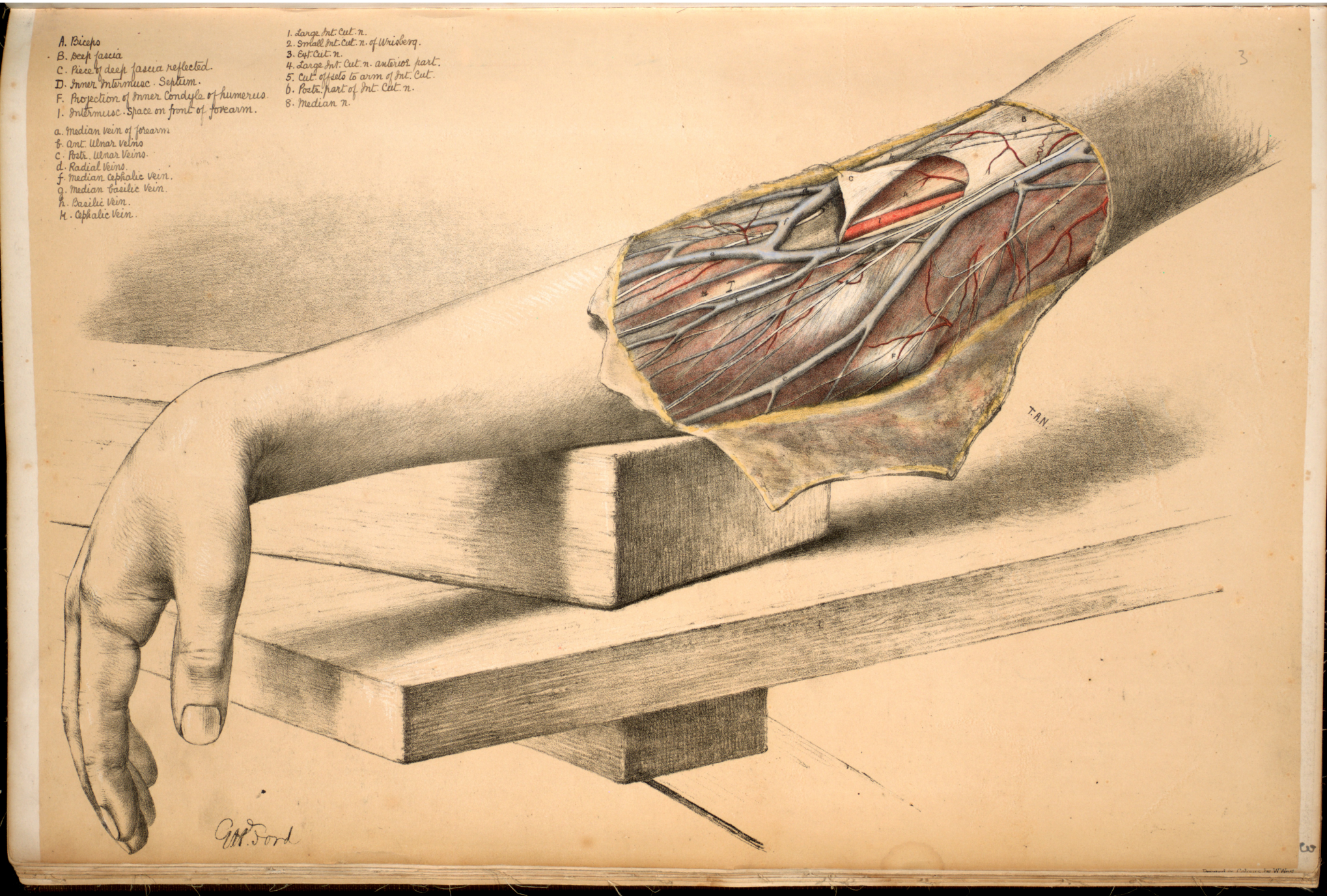
A. Biceps
B. Deep fascia
C. Piece of deep fascia reflected.
D. Inner Intermusc. Septum.
F. Projection of Inner Condyle of humerus.
I. Intermusc. Space on front of forearm.
a. Median vein of forearm
b. Ant. Ulnar Veins
c. Postr. Ulnar Veins.
d. Radial Veins.
f. Median Cephalic Vein.
g. Median basilic Vein.
h. Basilic Vein.
k. Cephalic Vein.
1. Large Int. Cut. n.
2. Small Int. Cut. n. of Wrisberg.
3. Ext. Cut. n.
4. Large Int. Cut. n. anterior part.
5. Cut. offsets to arm of Int. Cut.
6. Postr. part of Int. Cut. n.
8. Median n.
3
T.A.N.
G.W. Ford

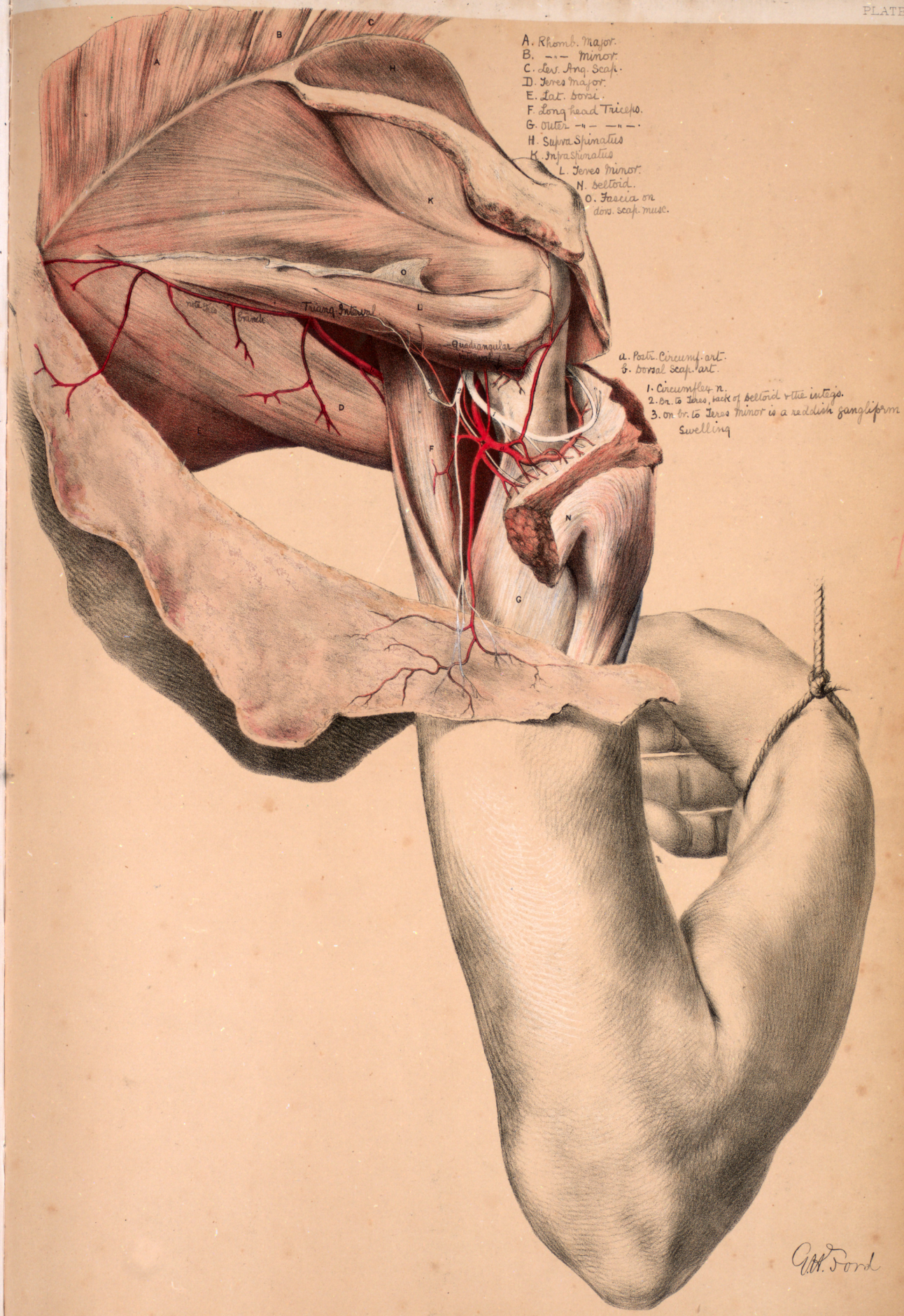

from a dissection by G.V.Ellis

London, Published May 1, 1863.

Printed in Colours by W.West.

PLATE VI.

Pl. 6.

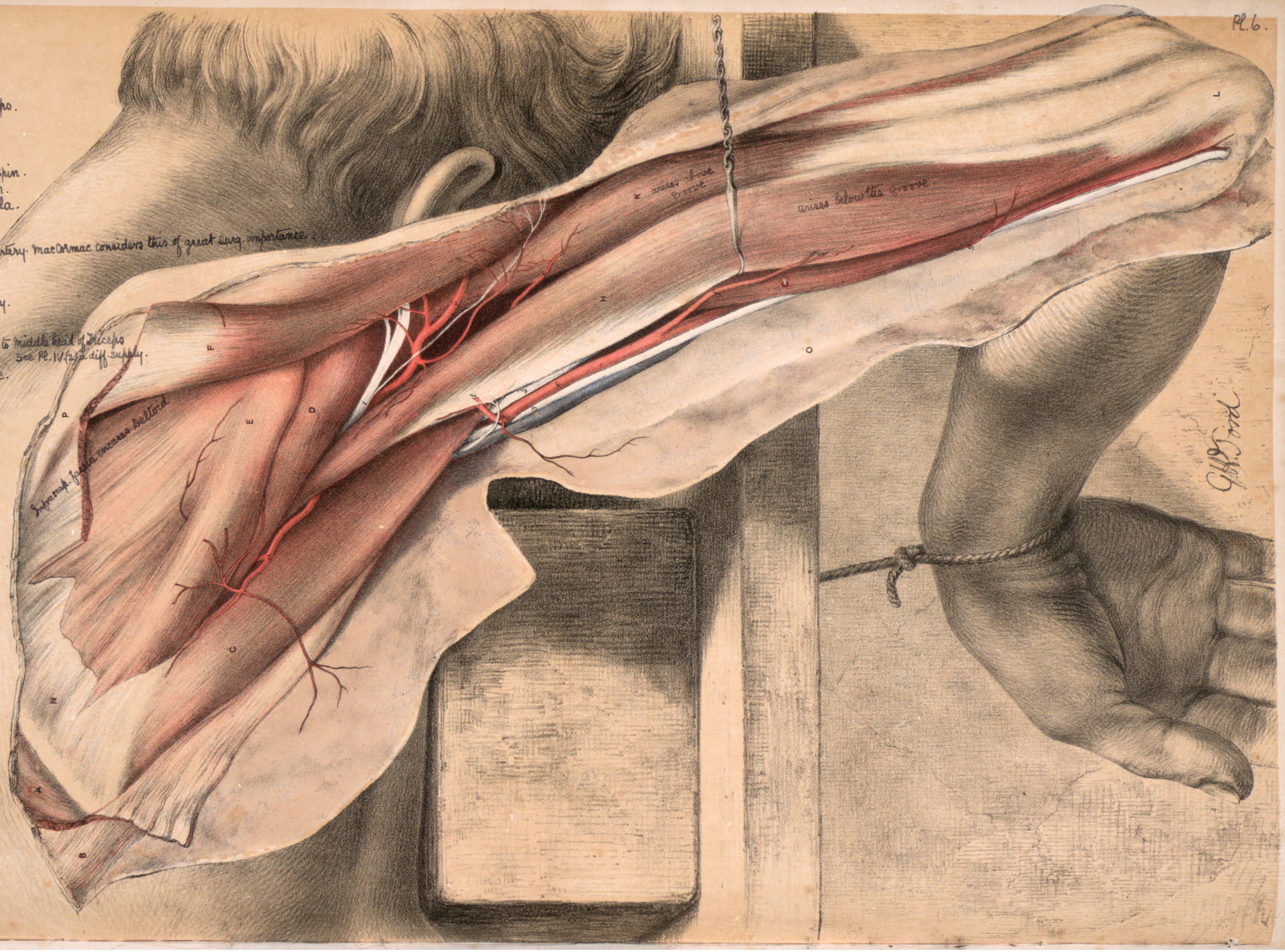

A. Rhomb. Major.
B. Lat. Dors.
C. Teres Major.
D. Teres Minor.
E. Infra Spinatus.
F. Deltoid Muscle.
G. Inner head of Triceps.
H. Middle " " "
K. Outer " " "
L. Tendon of Triceps.
N. Fascia over Infra Spin.
O. Fascia of the Arm.
P. Spine of the Scapula.

a. Dorsal Scap. artery.
b. Circumflex artery.
c. Musc. offset of Sup. Prof. artery. MacCormac considers this of great surg. importance.
d. Musc. Br. of Brachial.
e. Brachial Trunk.
f. Musc. Br. of Brachial.
g. Infr. Profunda artery.

1. Circumflex nerve.
2. Offset of Musculo Spiral to middle head of Triceps
3. Ulnar n.
4. Musculo Spiral nerve.

See Pl. IV (2) a diff. supply.

G. H. Ford

Printed in Colours by T. West.

London Published May 1, 1863.

Subscription by C. V. Ellis.

A. Lower end long head of Triceps cut.
B. Upper end " " " "
C. Outer head of Triceps.
D. F. Inner " " " "
E. Nerve & Vessels to anconeus in cut. inner head of triceps
G. Anconeus muscle. (really a contin. of outer fibres of Triceps.)
H. Supinator Longus.
K. Teres Minor.
L. Infra Spinatus.
M. Lat. Dorsi.
N. Teres Major.
P. Deltoid
Q. Outer Condyle of Humerus.
R. Olecranon process.
S. Fascia of forearm reflected.

a. Brachial artery.
b. Basilic Vein becoming axillary.
c. Sup. profunda artery.
d. Offset of profunda to front of the arm With the Musculo Spiral nerve.
f. Branch artery along outer intermusc. septum.
g. Musculating br. from the Recurrent Radial.
h. Anastom. br. from Inteross. Recurrent artery.
K. Musc. Br. & artery to triceps & anconeus.
L. Br. of art. from Post. Circumfl. to Teres Minor.
M. & N. Cut. & musc. offsets of Postr. Circumflex artery.

1. Musculo Spiral n.
2. 2. Ulnar n.
3. Offset to the long head triceps
4. Offset to inner head " " · see Pl. IV. p. 50.
+++ Three branches to outer head of Triceps.
6. Branch to anconeus.
7. Upper Cut. Cut. of Musculo Spiral n.
8. Lower — " — " —
9 nerve to the Teres Minor.
10. Cut. Br. of Circumflex nerve.

Dissection of the musculo spiral nerve at the back of the arm & Profunda artery.

PLATE VII

Dissection by G.V. Ellis

London. Published July 1. 1863.

Printed in Colours by W. Dickes

A. Biceps
B. Brachialis anticus
C. Pronator Teres.
D. Palmaris longus.
E. Flexor Carpi Radialis
F. Flex. digit. Subl.
G. Flex. Carp. Uln.
H. Flex. long. poll.
L. Supinator longus.
N. Palmaris Brevis.

P. Ext. Carp. Rad. Long.
S. Ext. Oss. Metacarp. poll.

a. Anast. br. of Brachial trunk.
b. End of Brachial artery.
c. d. unnamed Cut. Offsets from Brachial & Radial artery.
e. Radial artery
g. Superf. Volar branch.
h. Ulnar artery
n. Cut. Med. veins joining a deep companion vein.

1. Musculo Cut. n. br. = Ext. Cut.
2. 2. Median nerve.
3. Radial nerve
4. Cut. palmar Br. of median n.
5. Palmar part of the Ulnar nerve.

E. E. S.
Superf. & Deep muscles.

Inner Intermuscular Septum.

F. I. P.

Superfic. muscles 5 in number.
Deep muscles

F. S. digit.
Two Tendons in middle & ringfinger appear on surface
Issuing beneath lower border is the Median nerve.

Ext. Primi Intern. poll.

G. Conceals below the Ulnar Vessels & nerve.

G. V. Ford.

From a dissection by G.V. Ellis
London, Published July 1. 1863
Printed in Colours by W. West

To make this dissection - cut & remove the Inner group of the Superficial muscles seen in previous plate - except the Pronator Teres & the F. Carpi Uln. then draw up the pronator from the Ulnar vessels.

A. Lower end of Biceps.
B. Brachialis Anticus.
C. Supinator longus.
D. Pronator Teres.
F. Conjoined Palmaris Long. & Flex. Carp. Rad. cut & turned aside.
G. Flex. Carp. Uln.
H. Sup. Brevis.
J. Cut end Flex. Subl.
K. Flex. Long. Poll.
x. Ant. Annular Lig.
L. Flex. Prof. digit.
N. Slip of Flex. Long. Poll.
O. Ext. Oss. Metac. Pollicis.
P. Pronator Quad.
Q. Tendons of Flex. Subl. cut.
R. Tendon of Flex. Carp. Rad.

a. Brachial art.
b. Radial art.
c. Ulnar art.
d. Ant. Carp. br. of Radial Trunk.
e. Superf. Volar
g. Postr. Ulnar Recurrent.
K. Ant. Inteross.
n. Median artery.

1. Median n.
2. Ant. Inteross. br.
3. Ulnar nerve.
4. Brs. of Uln. nerve to Flex. Cap. Ulnaris.
5. Brs. of Uln. nerve to Flex. Prof. digit.
6. Brs. of " " cut. palmar br. of Ulnar.
7. Palmar Cut. nerve br. of Median nerve.

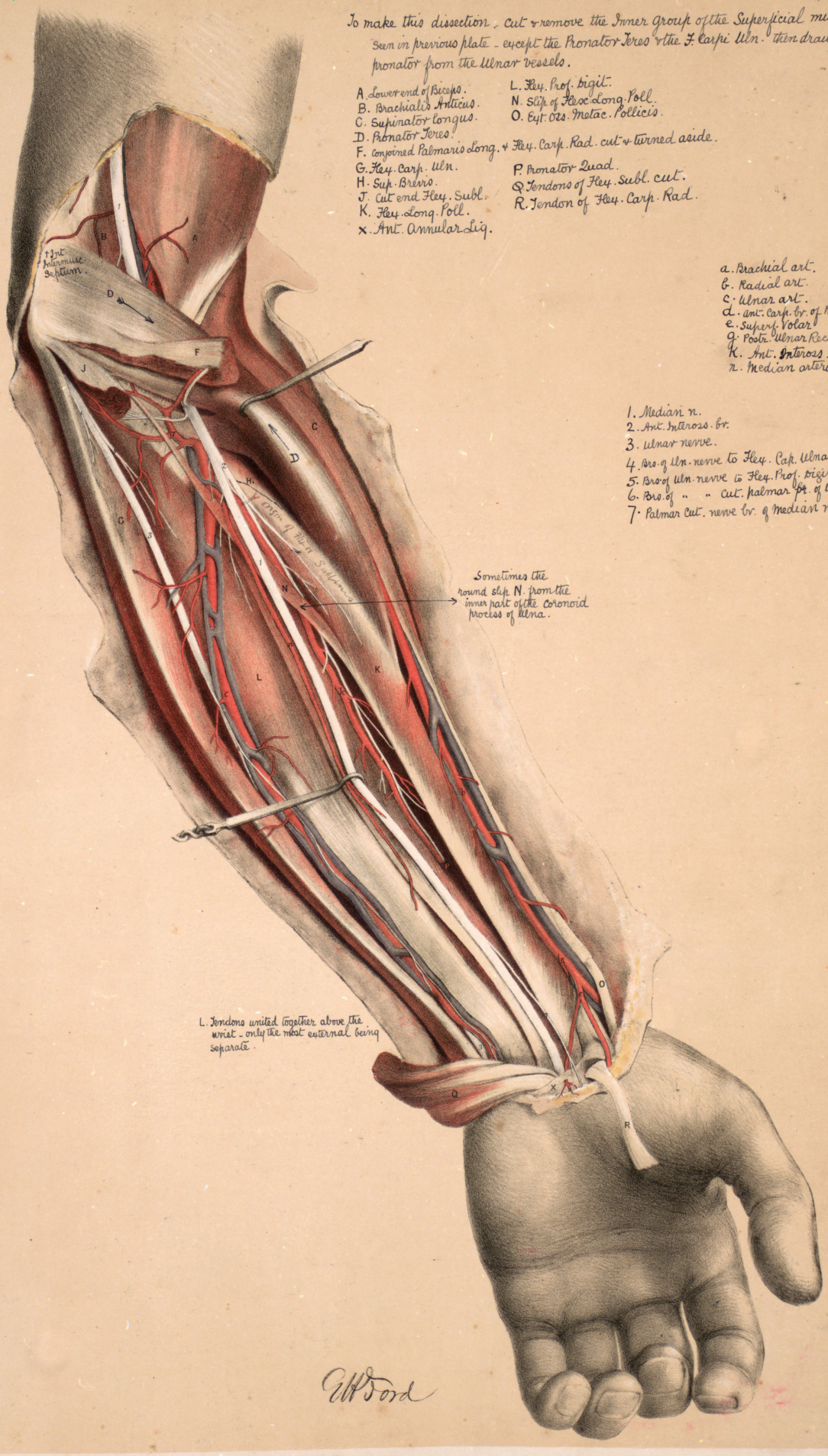

E H Ford

...m a dissection by G.V. Ellis
London Published September 1 1863
Printed in Colors by W. We...

Fig. 1. A. Palmaris Brevis
B. Abduct. Poll.
D. Hex. Brev. Poll. (outer head.)
E. Palmaris Longus
G. Add. Min. Digit.
H. Add. Poll.
J. Abd. Minimi Digit.
K. K. Pieces of the Sheath of the Hex. tendons.
L. Palmar fascia.
N. 1st dors. inteross.
O.O. Two outer lumbricales
R. Hex. Sub. Digit. tendons.
S. Hex. Carp. Uln. tendon.
V. Hex. Sub. tendons in palm.
W. Hex. Prof. tendon to ring finger.
X. Ant. Annular liq.

Fig 1.

a. Ulnar art. in forearm.
b. Radial " " "
c. Superf. palmar arch.
d. Superf. Volar
f. 4. dig. br's. of Superf. palmar arch.
g. Commun. br. from palmar arch to Radial br. of Index finger
h. " " to the deep arch from the digit. art. of little finger.

The median & ulnar nerves divide in the palm
1. Median n. trunk.
2. 1st dig. br.
3. 2nd " "
4. 3rd " "
5. 4th " "
6. 5th " "
7. Communicating br. from median to ulnar.
8. Outer dig. br. ulnar.
9. Inner dig. br. ulnar.
10. Trunk of Ulnar n.

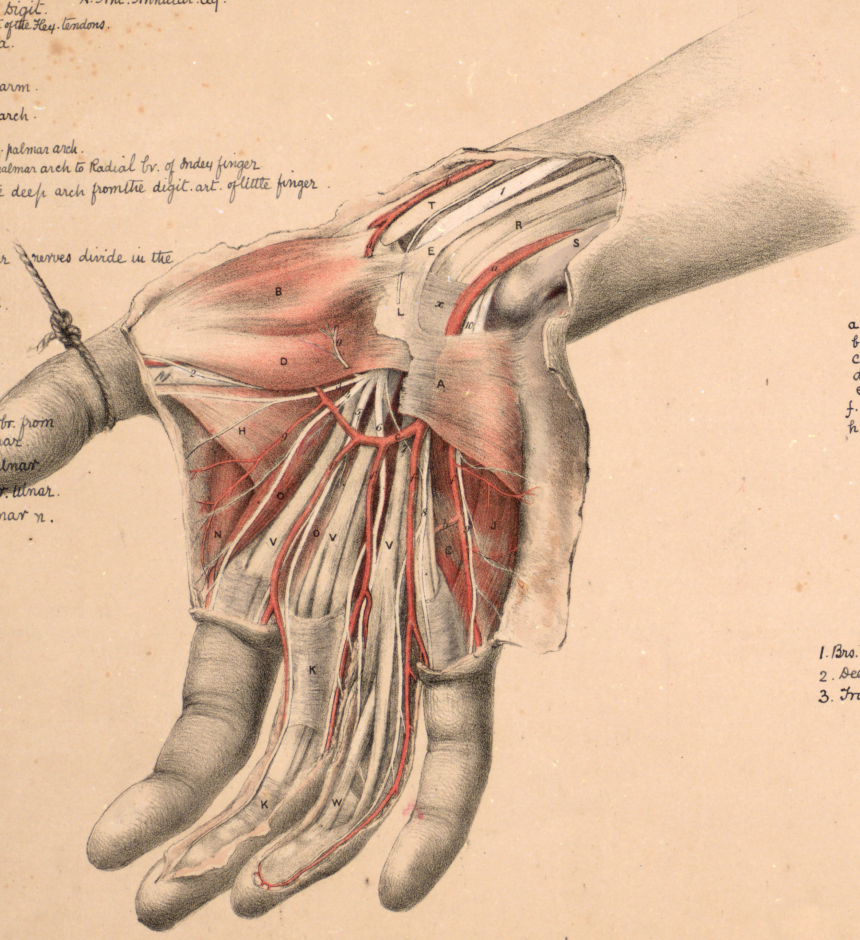

Dissection.
Superf. palmar arch - ulnar & median n's. are to be cut through at the annular liq. cut & throw forwards the Superf. & Deep Hexor tendons.

Fig 2.

Fig. 2. B. Abd. Poll.
C. Opp. Poll.
D. Hex. Brev. Poll. (outer head)
F. " " " (inner head)
H. Add. Poll.
J. Abd. minimi dig.
K. Hex. Brev. Min. dig.
L. Add. Min. dig.
M. Hex. long. poll. tendon.
N. 1st dors. inteross.
O. Lumbricales muscles.
P. Inteross. of hand.
R. Hex. Sub. Dig. tendons.
S. Hex. Carp. Uln. "
T. Hex. Carp. Rad. "
V. Hex. Profund. "

a. Deep palmar arch.
b. Prof. br. of Ulnar art.
c. Large artery of thumb.
d. Dig. art. to radial side of the forefinger
e. Comm. br. to deep arch from dig. art. to little finger.
f. f. Two inner Inteross. arts.
h. h. Offsets to lumbrical muscles

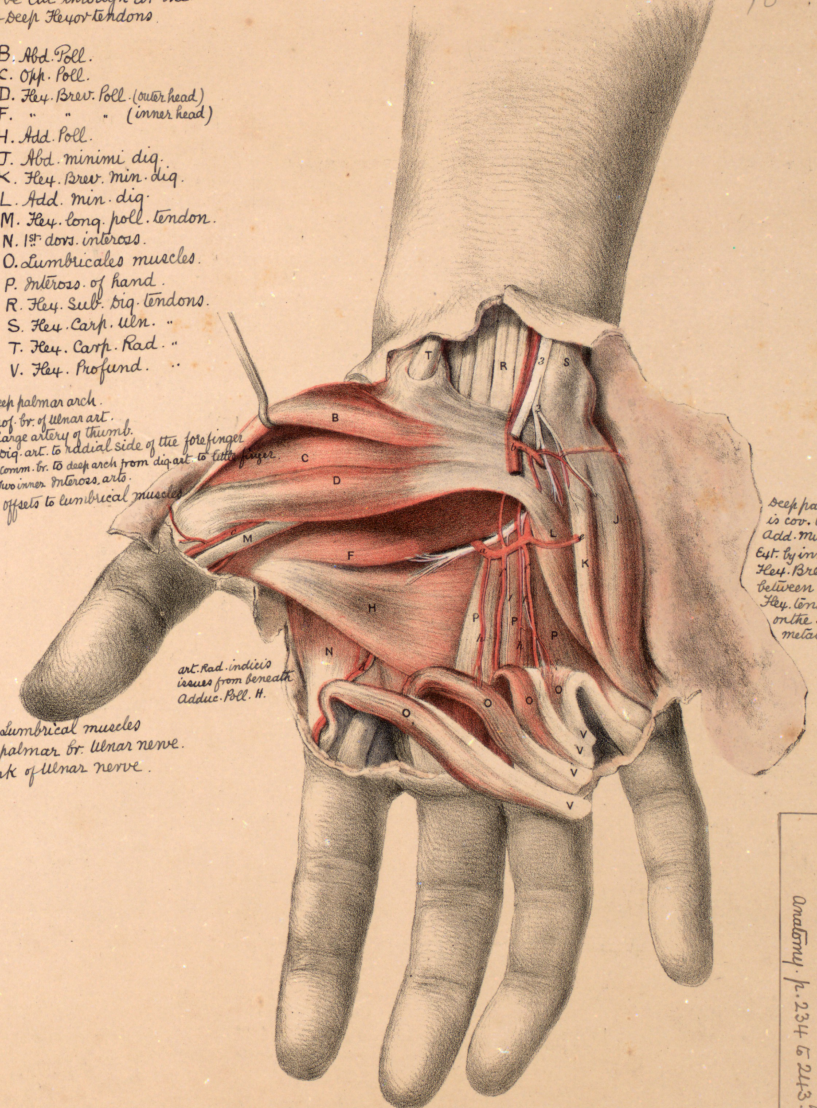

Deep palmar arch is cov. internally by Add. Min. Dig. L. Ext. by inner head of Hex. Brev. Poll. F. & between these by the Hex. tendons. It rests on the 3 middle metacarpal bones.

art. Rad. indicis issues from beneath Adduc. Poll. H.

1. Brs. to Lumbrical muscles
2. Deep palmar br. Ulnar nerve.
3. Trunk of Ulnar nerve.

For effects of Wounds above Wrist involving median & Ulnar nerves see Box & Eccles Clinical applied Anatomy. p. 234 to 243.

E H Ford

10

A. Biceps
B. Supinator long.
C. Ext. Carp. Rad. long.
D. " " " Brevior.
E. Ext. Comm. digit.
F. Ext. Min. digit.
G. Ext. Carpi ulm.
H. anconeus
J. Brach. Antic.
K. Ext. Ou Met. Bell.
L. Ext. Primi Internod. Bell.
N. Ext. Secund " "
O. Intr. Interos
P. Fibrous bands forming Sublinear ligaments
R. Extension from
S. Slitting septa Extensor tendons
T. Insertion of Ext. tendon into base phalanx
V. Tendon of Indicator muscle.
X. Post annular lig.
+ deep fascia.

a. Radial artery
b. Post. Carpal br.
c. Metacarp. Pr.
d. bor. br. of the thumb-radial
f. bor. Indic. arter. finger.
g. br. Post. Interos. artery
K. Post. part of Interos. artery Ant.
K. Offset from Interos artery.
+++. Cut. Offsets of Post. Interos. artery.

antagonists as Extn
Supin = Pron.
this Post. group includes
their antagonists. Ext. Carp.
E.E.S.

G.V. Ford

From a dissection by G. V. Ellis.

London, Published November 1. 1863.

Printed in Colours by W. West.

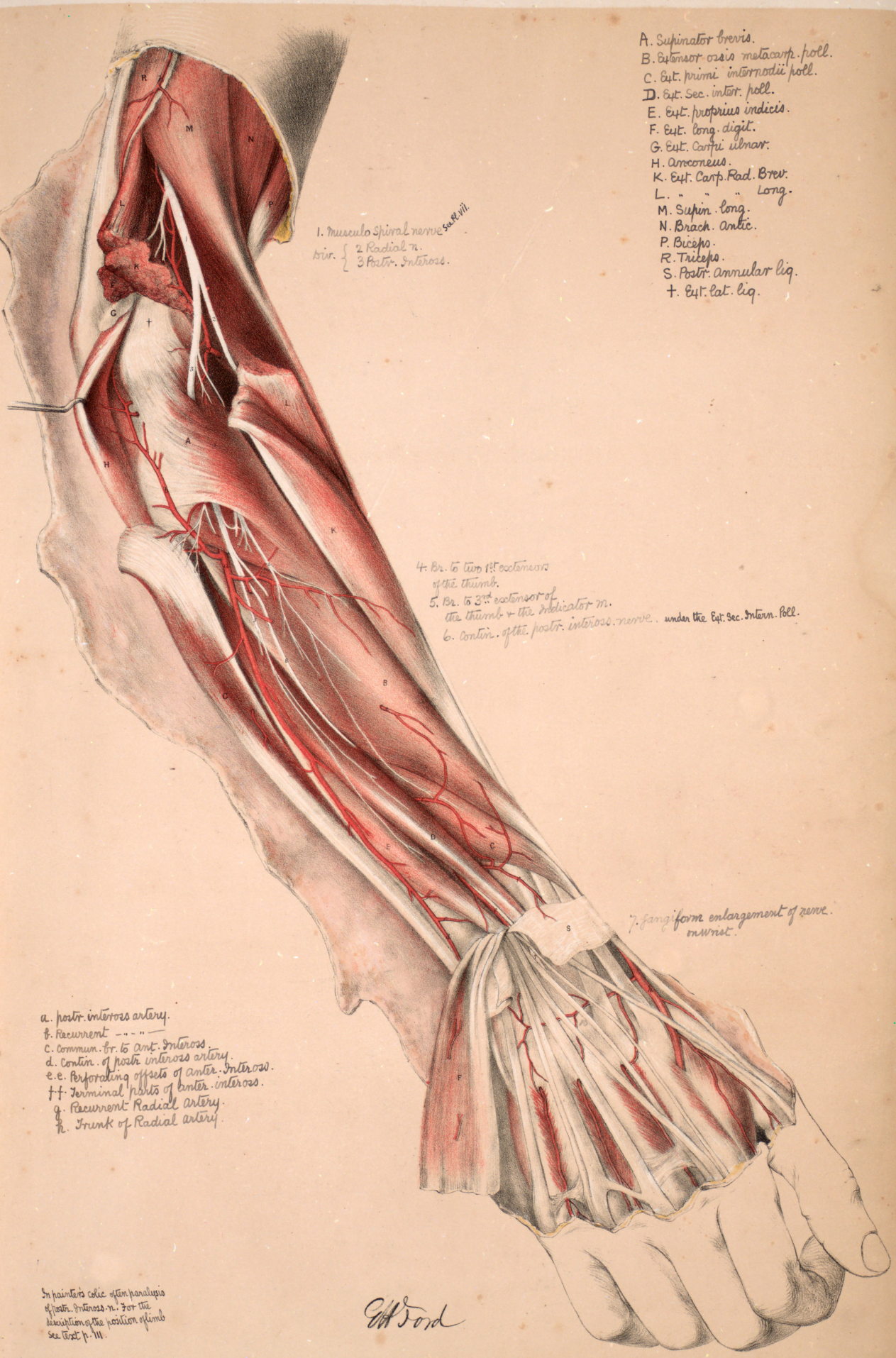

From a dissection by G.V. Ellis

London, Published November 1. 1863.

Printed in Colours by W. West

Conjunctiva

Retro tarsal fold. ← Tarsal or palpebral.

Sclerotic coat. Bulbar. Limbus or part overlapping the Cornea.

Sulcus or fornix } adenoid tissue + usually follicles.

post. conjunctival vessels derived from the palpebral vessels

Cornea

plica semil. Caruncle

Subtarsal Suture

Eyelid Aid

The ant. Cil. arts. are derived from the Musc. Trs. run with the tendons of the Recti to form a vascular zone near the cornea beneath the Conjunct. They then pierce the sclera & terminate in the Cir. Major Irides.

↓ anter. conjunct. vessels from the anterior ciliary vessels (episcleral vessels) & do not move with conjunctiva like the others do.

2. Optic n. & Commissure.
3. Motores Oculi.
4. Trochlear nerve.
5. Trifacial nerve.
6. Abducens.
7. Facial.
8. auditory.
9. Glossopharyngeal n.
10. Pneumogastric.
11. Spinal accessory n.
12. Hypoglossal n.
13. Gasserian gangl.
14. Ophthal. nerve
15. Supr. Max. n.
16. Inf. Max. n.
17. Large Petrosal n.
18. Supra orbit. n.
19. Lachrymal nerve. 21 Upper. br. of 3rd n.
23. Contin. of nasal nerve

All the n's. crossing the middle fossa i.e 3rd 4th 5th 6th, communicate with the Symp. on the Carotid.

The small root of the 5th lies under the large one & will be seen on raising the ganglion. It is unconnected with the gang. & belongs exclusively to the Inf. Max. trunk.

a. Int. Carotid artery.
b. Vertebral artery.
c. Large Meningeal artery.
m. Poste. Meningeal "
n.n. Anter. Meningeal arteries.

L. Lachrymal gland.
M. Left eyeball
N. Supr. Oblique
P. Levr. Palp. Sup.
R. Upper Rectus.
S. Ext. Rectus.
T. Pulley Supr. Obliqe.

Vessels of Orbit.
d. Ophth. artery
e. Ant. Ethmoid or Nasal artery.
f. Poste. Ethmoid
g. Supra orbital artery.
h. Ophth. Vein. (see Pl. XIV. Q.)

Deep dissect.

Superf. dissect.

q. 10. 11. Pass through diff. compartments of Foramen jugulare.
10. 11. in Same fibrous Sheath.

Large 7th Petrosal n. in a bony groove under the base of Ganglion.

The nerves crossing the Middle fossa are invested by sheaths of Dura Mater – the others are free until they enter their foramina of exit. On the Left side the place of entrance into the Sheaths may be seen. It is removed on the right side.

aperture.

11. This nerve not attached to brain enters skull leaves it by one

G. Straight Sinus.

E H Ford

from a dissection by G.V.Ellis.

London, Published Jan.1,1864.

Printed in Colours by W.West.

δολίχος long κεφαλή = head
βραχίων arm " "
μεσάτης medium " "

πρό = before γναθος = jaw
μέσος = middle " " pertaining to premaxillary bone. gnathic index 98 to 103.
ὀρθός = straight " gnathic index less than 98.

The middle cranial fossa &
" fossa for sigmoid sinus
are nearer the Ext. Audit. Canal &
the Tympanic cavity & the
Mastoid antrum
in brachycephalic skulls than
in dolichocephalic heads.

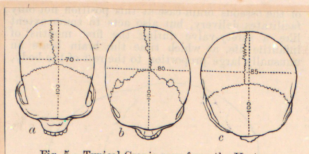

Fig. 5.—Typical Crania seen from the Vertex: a, Negro, index 70, Dolichocephalic; b, European, index 80, Mesaticephalic; c, Samoyed, index 85, Brachycephalic. (After Tylor.)

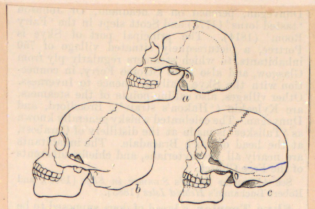

Fig. 6.—Lateral View of three typical Skulls: a, Australian, prognathous; b, African, mesognathous; c, European, orthognathous. (After Tylor.)

2. Optic nerve
3. 3rd n.
4. 4th n.
5. 5th n.
6. 6th n.
13. Gasserian ganglion.
20. nasal n. at its origin.
21. upper br. of 3rd.
22. Lower br. " " .
23. nasal n. leaving Orbit.
24. Infratrochlear n.
25. Lenticular gang.
26. Long root of lentic. g. to nasal n.

4 parts of Optic nerve.

1. The intracranial. 1 c.m. long.
2. The intra canalicular { (a) bony 4 m.m. (b) fibrous extending into cranial cavity. = 2 m.m.
3. Intra orbital 3 c.m. lax & S shaped. to permit of rotation.
4. Intra-ocular piercing sclera & choroid = 1·25 m.m. long.

The Central artery & Vein of the Retina enter the Optic n. 10 m.m. behind the globe.

4th & last stage. 3rd stage of dissection.

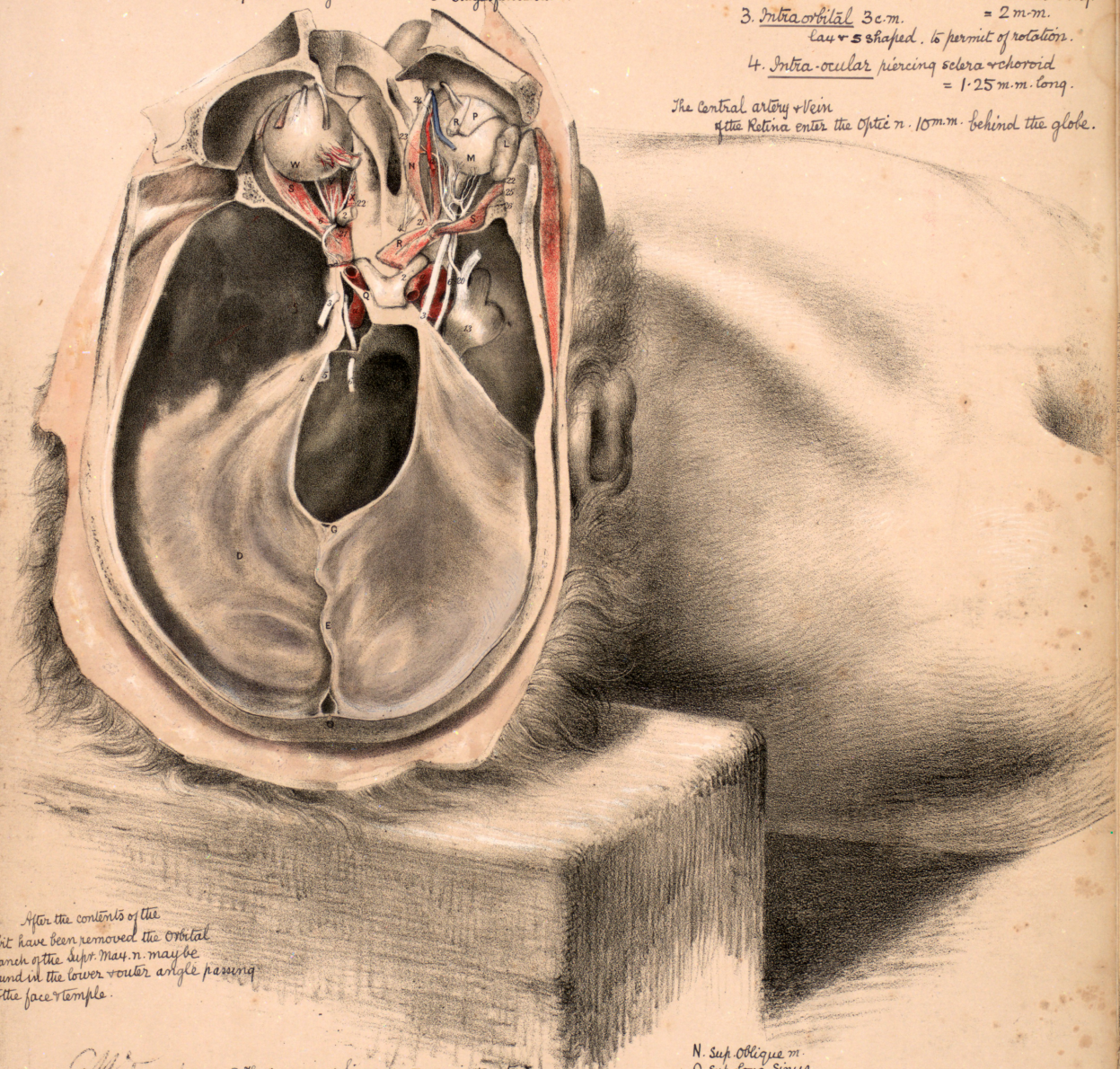

After the contents of the orbit have been removed the Orbital branch of the Supr. Max. n. may be found in the lower & outer angle passing to the face & temple.

G.W. Ford

Q. The Cavernous Sinus. (for structures in the outer boundary see Pl. XIII.)

N. Sup. Oblique m.
O. Sup. Long. Sinus.
P. Lev. Palp. Supr.
Q. Cav. Sinus.
R. Supr. Rectus.
S. Ext. Rectus. (note the nerves passing between its heads) 3rd, nasal of 5th, 6th.
V. Infr. Rectus.
W. Infr. Oblique.
X. Int. Rectus.

The Dura at base, the Cavernous Sinus, the dissection of Orbit in its two deeper stages.

a dissection by G.V. Ellis. London, Published Jan 1, 1864 Printed in Colours by W

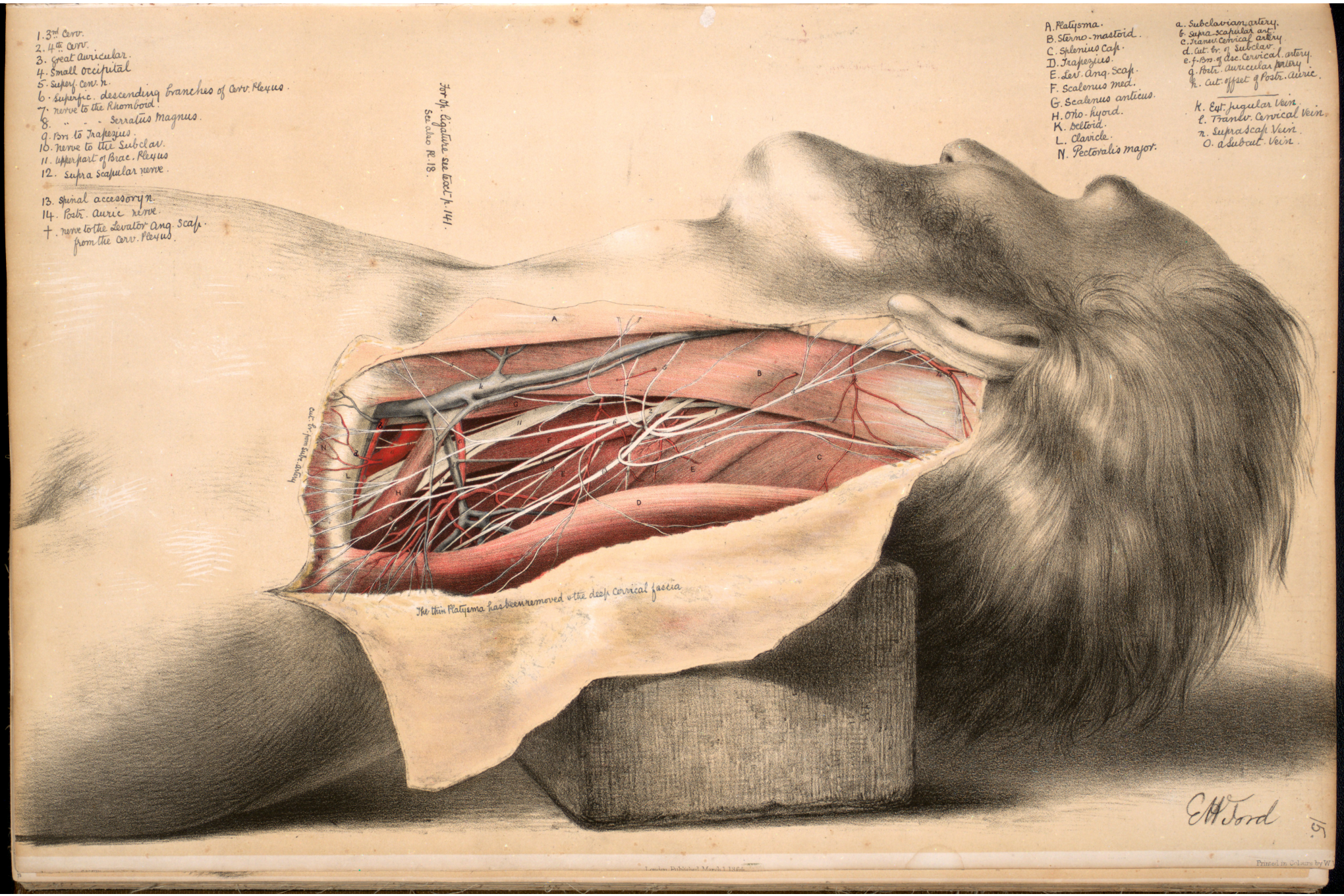
1. 3rd Cerv.
2. 4th Cerv.
3. Great Auricular.
4. Small occipital
5. Superf. Cerv. n.
6. Superfic. descending branches of Cerv. Plexus.
7. nerve to the Rhomboid.
8. " " " Serratus Magnus.
9. Brs. to Trapezius.
10. nerve to the Subclav.
11. upper part of Brac. Plexus
12. Supra Scapular nerve.
13. Spinal accessory n.
14. Postr. Auric nerve.
†. nerve to the Levator Ang. Scap. from the Cerv. Plexus.
For Op. ligature see text p. 141. See also Pl. 18.
A. Platysma.
B. Sterno-mastoid.
C. Splenius Cap.
D. Trapezius.
E. Lev. Ang. Scap.
F. Scalenus med.
G. Scalenus anticus.
H. Omo-hyoid.
K. Deltoid.
L. Clavicle.
N. Pectoralis major.
a. Subclavian artery.
b. Supra-scapular art.
c. Transv. Cervical artery
d. Cut. br. of Subclav.
e. f. Brs. of Asc. Cervical artery.
g. Postr. auricular artery
h. Cut. offset of Postr. auric.
k. Ext. Jugular Vein.
l. Transv. Cervical Vein.
n. Supra Scap. Vein.
O. a Subcut. Vein.
Cut. br. from Subc. artery
The thin Platysma has been removed & the deep cervical fascia
E H Ford
15.

Laryngo-tracheal Trunk to be seen whilst Sterno mastoid keeps in position.

a. Facial artery & Vein.
b. Submental br. of facial.
c. Lingual artery & Vein
d. Offset of Sup. Thyroid art. to Lymph. glands.
ee. Superf. offsets of Sup. Thyroid.
ff. Infer. brs of Subcl. & Carotid arts.
g. Cut offsets of Poster. auric. artery.

k. Ext. jug. Vein.
l. Ant. jug. Vein.
n. facial Vein.

1. Cervical part of facial nerve.
2. Superf. Cerv. N.
3. Great auric n.

A. Platysma myoides.
B. Sterno-cleido-mastoid.
C. Thyro-hyoid.
D. Omo-hyoid.
E. Sterno-hyoid.
F. Ant. belly of digastric.
H. Stylo-hyoid.
J. Hyoid bone
K. Submaxillary gland.
L. Parotid gland.
N. Process of deep cervical fascia fixing Sterno-mast.
+ Lymphatic glands.

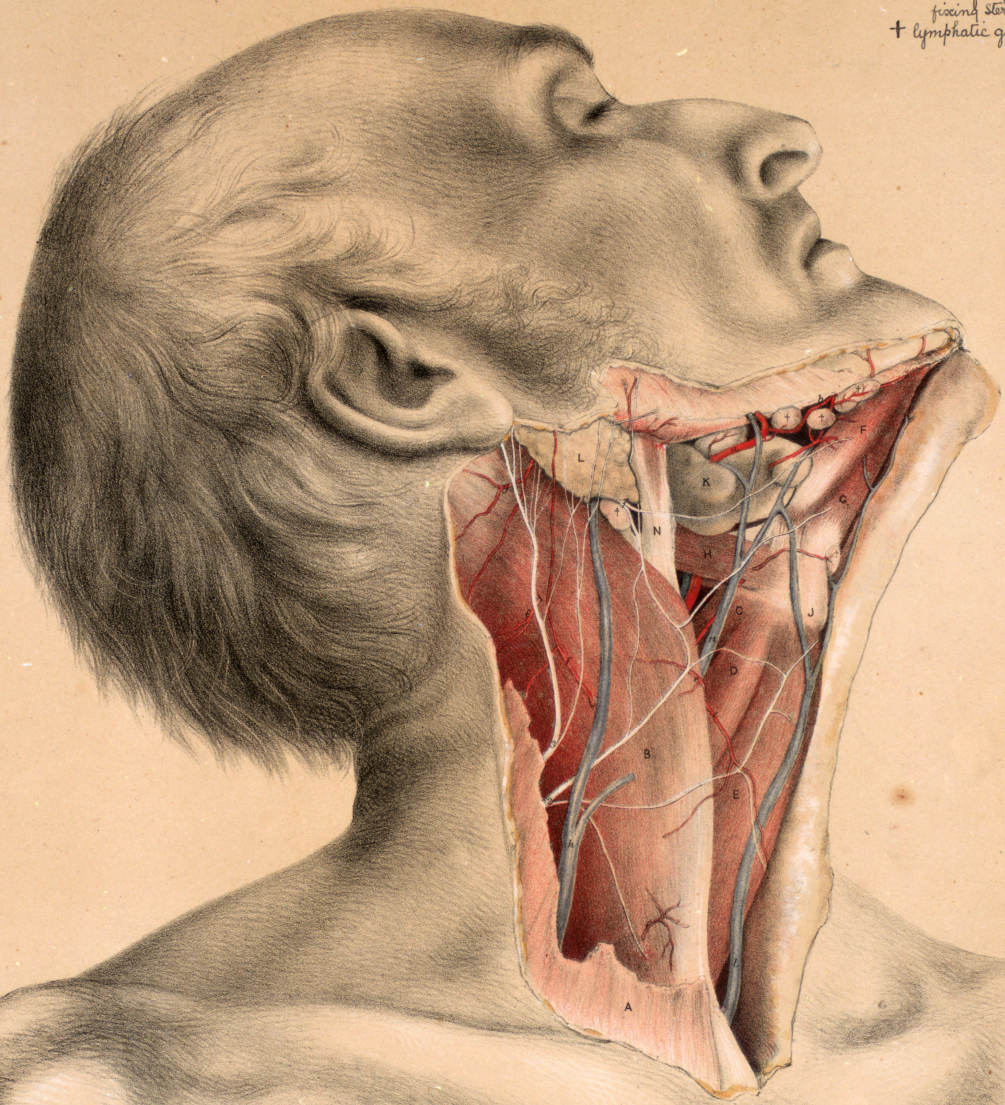

E.H. Ford

From a dissection by G.V.Ellis. London, Published March 1, 1864. Printed in Colours by W.West.

Only one Spinal nerve is seen in this dissection.

a. Common Car. art.
b. Ext. Car. art.
c. Int. Car. art.
d. Sup. Thyroid Art.
e. Lingual art.
f. Facial art.
g. Occipital art.
h. Postr. Auric. art.
i. Superf. Temp. art.
n. Int. maxill. art.
X. Spot for ligature of the C.C. Art. in the angle formed by the Omo-hyoid & the Sterno-mastoid

p. Int. Jug. Vein.
r. Ext. Jug. Vein.
s. Ant. Jug. Vein.

1. Supr. laryng. n.
2. Ext. laryng. n.
3. Desc. noni n.
4. Facial n.
5. Temporo-fac. br. of facial.
6. Cervico-fac. " "
7. N. to digastr. and Stylo-hyoid m.
8. Postr. auric. n.
9. Brs. of great auric. n. joining the facial n.
10. Great auric. n.
11. auriculo-temp. br. of 5th n.
12. Mylo-hyoid br. 5th.
13. Spinal access. n.
14. Hypogloss. n.

A. Sterno-mastoid.
B. Sterno-hyoid.
C. Omo-hyoid (ant. belly.)
D. Sterno-thyroid.
E.
F. Thyro-hyoid.
G.
H. Digastric (Ant. belly.)
N. Hyo-glossus.
P. Stylo-hyoid.
R. Digastric (Postr. belly.)
S. Masseter.

If operating on the left side remember that the Vein lies over the artery & would require turning on one side. This may even be required on the R. side but not usually.

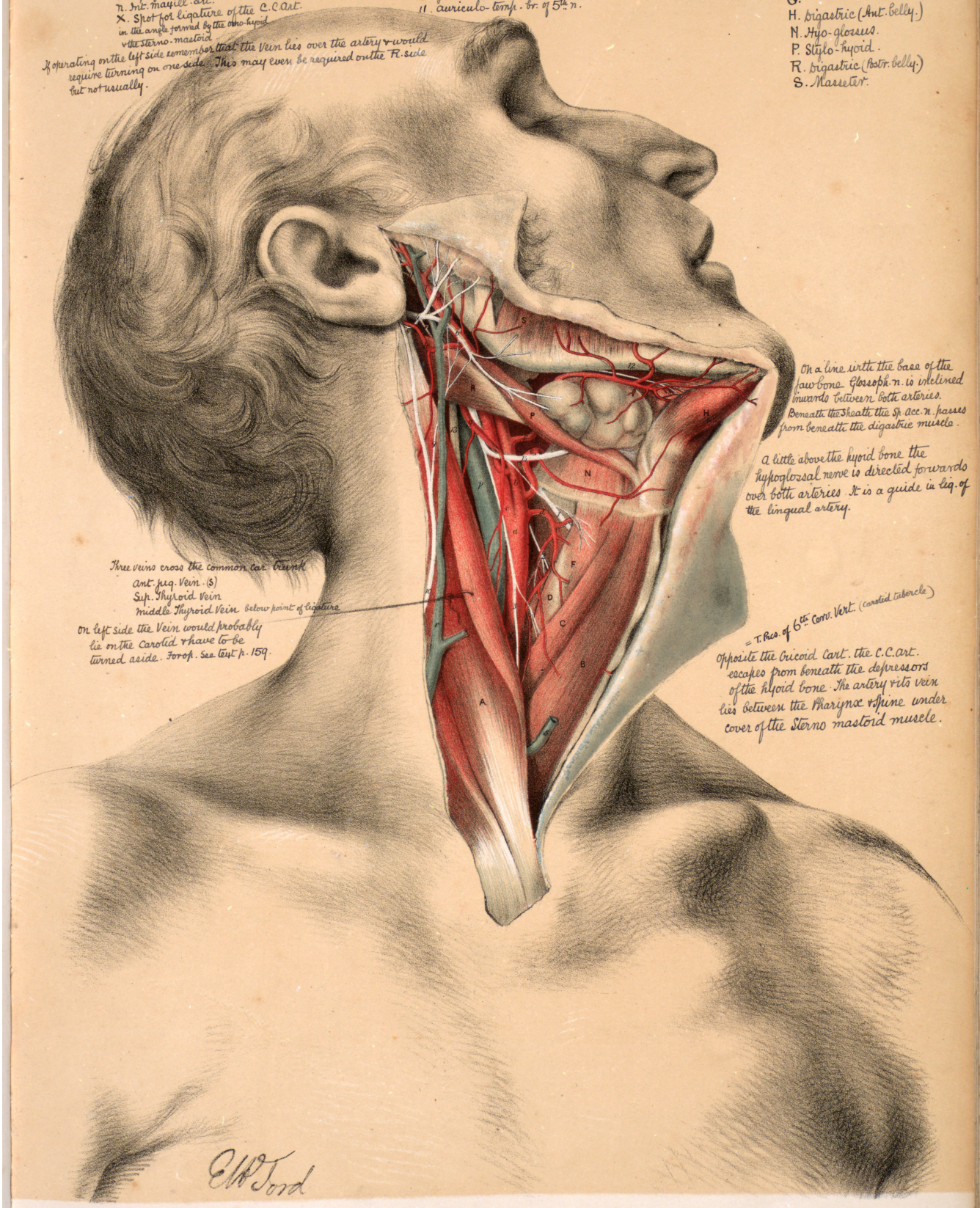

On a line with the base of the jaw bone Glossoph. n. is inclined inwards between both arteries. Beneath the Sheath the Sp. acc. n. passes from beneath the digastric muscle.

A little above the hyoid bone the hypoglossal nerve is directed forwards over both arteries. It is a guide in liq. of the lingual artery.

Three veins cross the common car. trunk
Ant. jug. Vein. (S)
Sup. Thyroid Vein
Middle Thyroid Vein below point of ligature

On left side the Vein would probably lie on the Carotid & have to be turned aside. For op. See text p. 159.

= T. Pros. of 6th Cerv. Vert. (carotid tubercle)

Opposite the Cricoid Cart. the C.C. art. escapes from beneath the depressors of the hyoid bone. The artery & its vein lies between the Pharynx & Spine under cover of the Sterno mastoid muscle.

E W Ford

Dissection by G V Ellis
London, Published May 1, 1864
Printed in Colours by

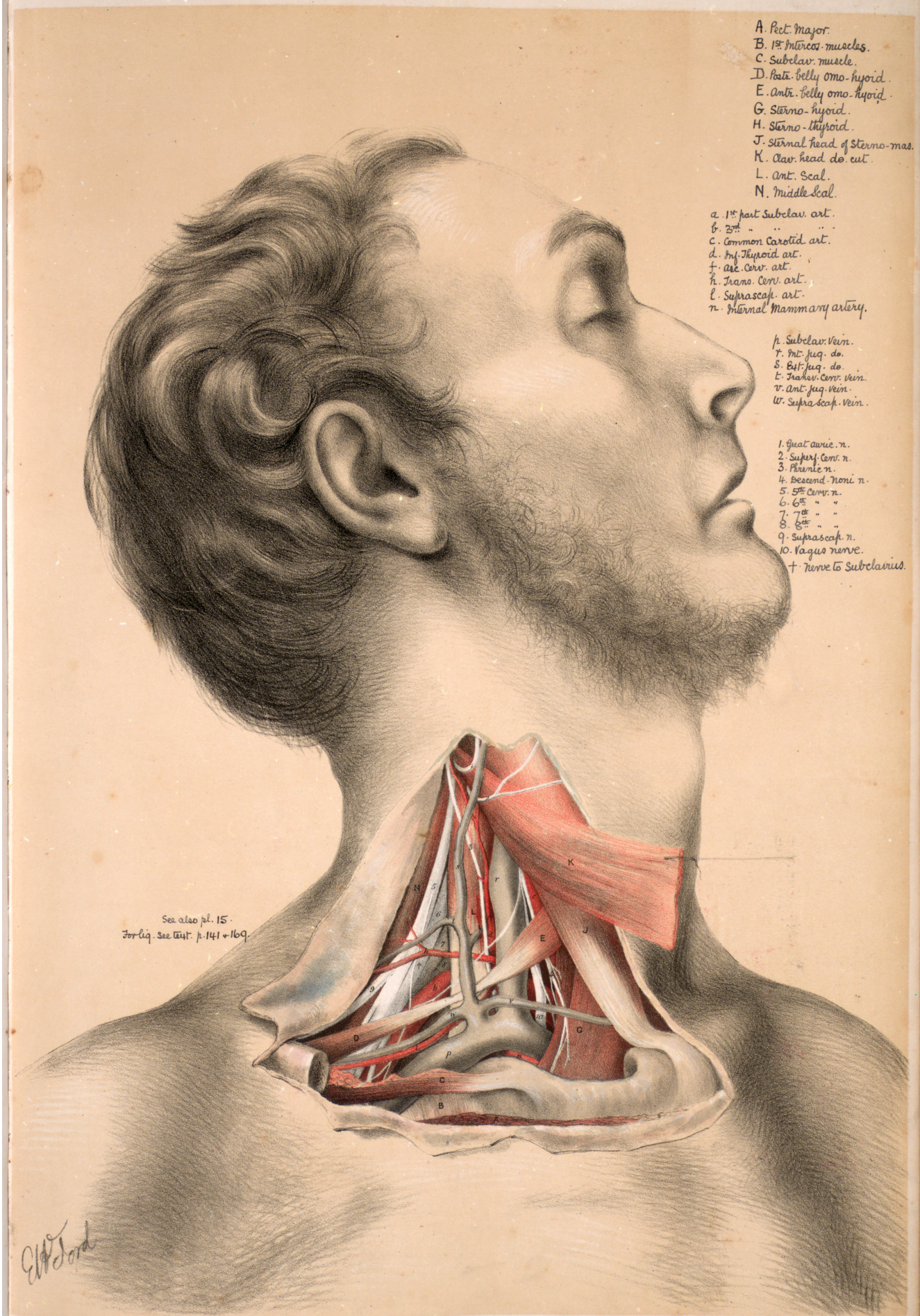

From a dissection by G. V. Ellis

London, Published May 1, 1864.

Printed in Colours by W. West.

A. Sterno-mastoid
B. Complexus cut through.
C. Semispinalis colli.
D. Inf. Oblique.
F. Sup. Oblique.
G. Rect. Cap. Post. major.
H. " " " minor.

a. occip. artery
b. Prof. Cervic. br. of occip.
c. Offset to the Small Recti.
d. Vertebral artery.
e. cervical br. of Vert. art.
f. anast. of Vert. & Prof. Cerv.
g. Deep Cervical artery.
h. Dorsal arteries (inner branches)

1. 1st or Suboec. n.
2. 2nd Cervic. n.
3. 3rd Cervic. n.
4. 4th Cervic. n.
5. 5th " "
6. 6th " "
7. 7th " "
8. Small Occip. nerve.

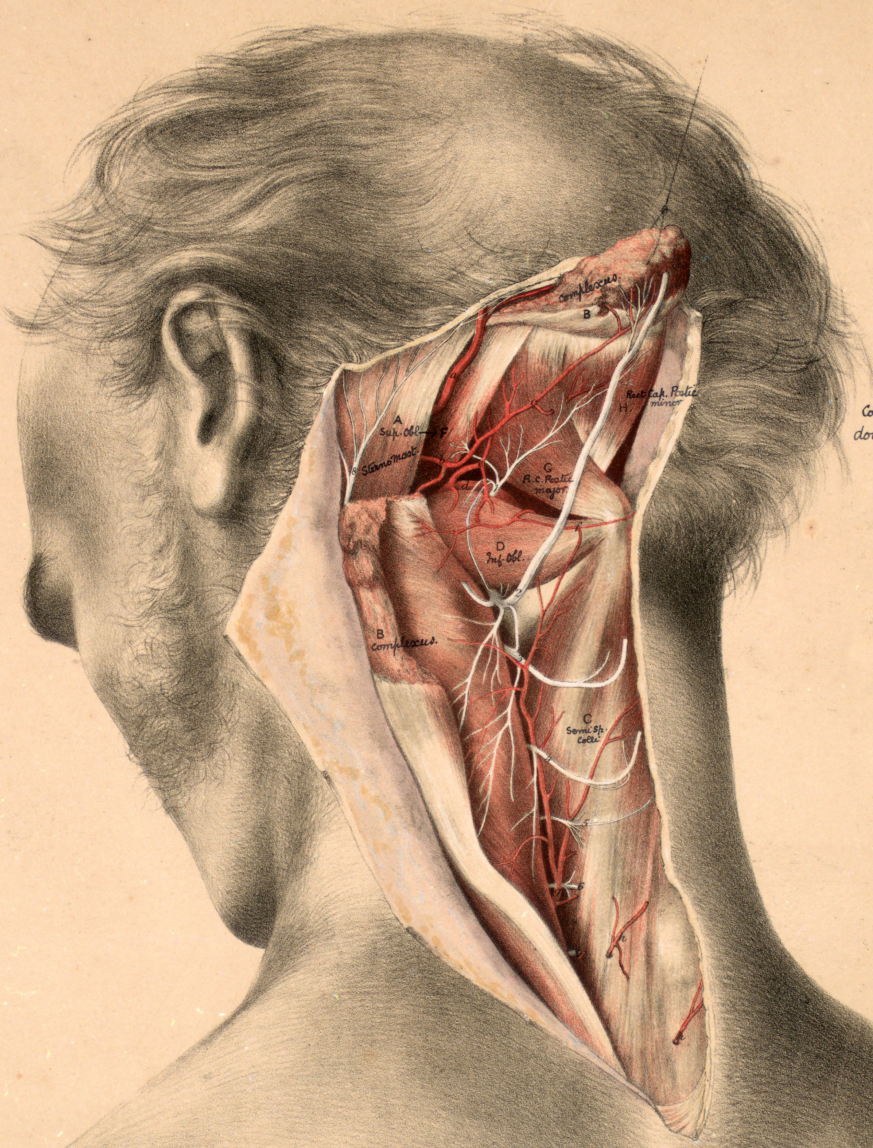

Complexus divided & thrown down and out.

E.H. Ford

From a dissection by G.V.Ellis.

London, Published July 1, 1864.

Printed in Colours by W.West.

For dissection to expose this see text p. 176.

A. Temporal muscle.
B. Ext. Pterygᵈ.
C. Int. Pterygᵈ.
D. Buccinator muscle.
F. Masseter muscle.
G. Digastric (postr. Belly)
H. Stylo-hyoid.
L. Stylo glossus.
N. Intern. lat. lig.
O. Styloid process.
P. Inlet of the Parotid gland.

a. Ext. Car. Art.
b. Postr. auric.
C. Superf. Temp.
d. Int. Max.
e. Inf. dental
f. Br. with the quadratory n.
g. Deep Temporal.
h. Buccal art.
l. Postr. dental br.
n. Facial art.
r. Inf. Labial br.
S. Masseteric br. cut.

t. Ext. jug. Vein.
v. Sup. Temp. Vein.
w. Int. Max. Vein.
x. Facial Vein.
z. Deep facial or ant. int. max. V.

1. Auriculo-temp. n.
2. Inf. dental n.
3. Quadratory n.
4. Masseteric n. cut.
5. Buccal n.
6. Postr. dental n.
8. Buccal brs. of facial n.

The large trunk of the 5th nerve leaves the Skull is covered by Ext. Pterg. B.

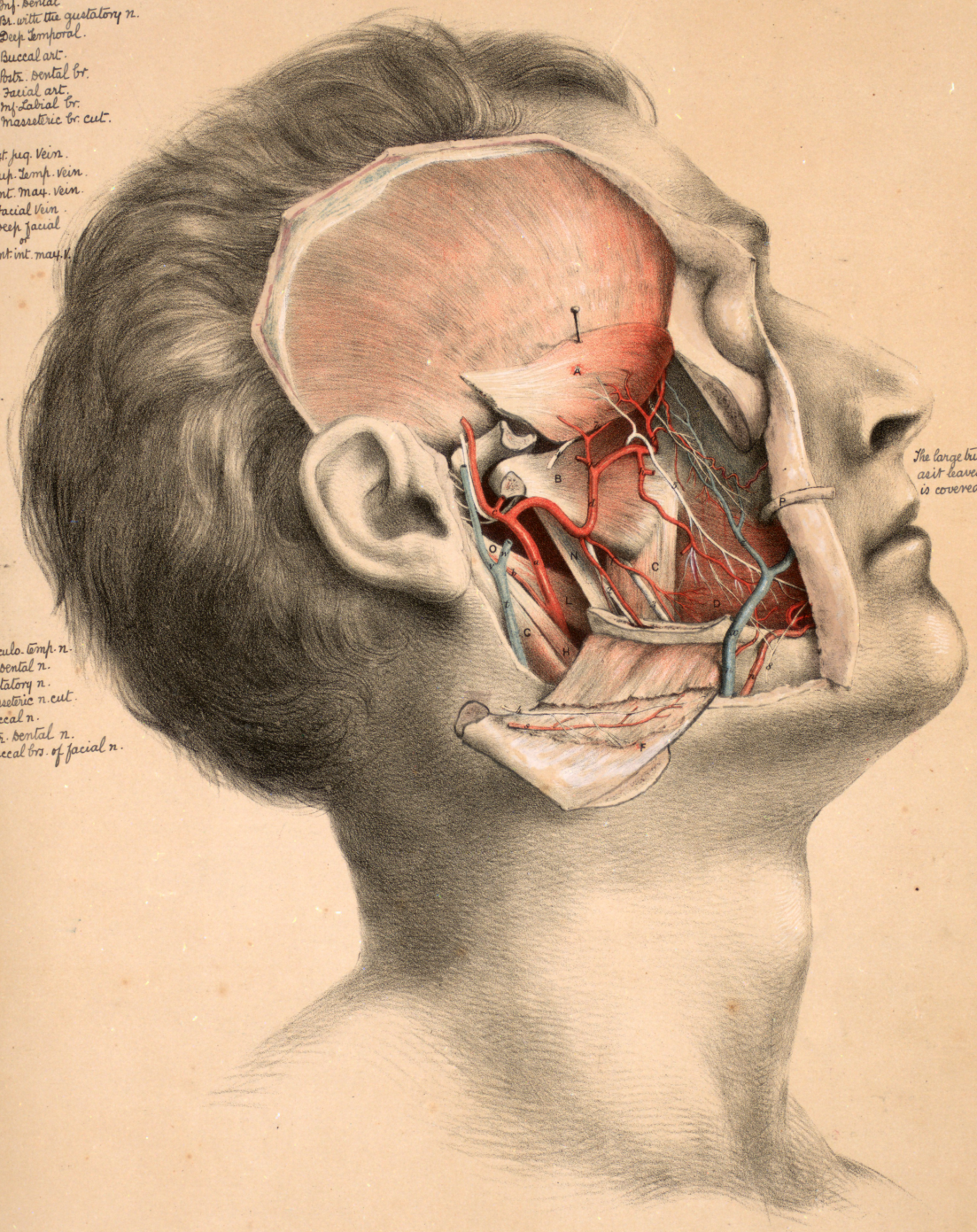

C. V. Ellis

From a dissection by C.V.Ellis.
London, Published July 1, 1864.
Printed in Colours by W.West.

To prepare this dissection - cut through the internal maxillary artery
disartic. the condyle of the jaw + draw it forwards with
the Ext. Pterygoid muscle.

A. Temporal muscle.
B. Ext. Pteryg.
C. Int. Pteryg.
D. Buccinator.
F. Masseter.
G. Digastric.
H. Zygoma thrown down.
L. Condyle of the Jaw.
N. Int. Lat. lig.
O. Styloid pres. + Stylo max. lig.

a. Ext. Car. Artery.
b. Large meningeal art.
c. Small meningeal.
d. Int. max.
e. Inf. dental.
f. Branch with the gustatory nerve.
g. Post. Temporal Brs.
h. Buccal br.
i. Post. Dental br.
k. Facial artery.
l. Ext. jug. Vein.

1. auric-temp. n.
2. Inf. dental nerve.
3. Gustatory n.
4. masseteric br. cut.
5. Buccal branch.
6. Chorda tympan n.
7. Mylo-hyoid br.
8. Deep Temporal br.
9. Br. to Ext. Pterygoid.
4 " " Int. " " "

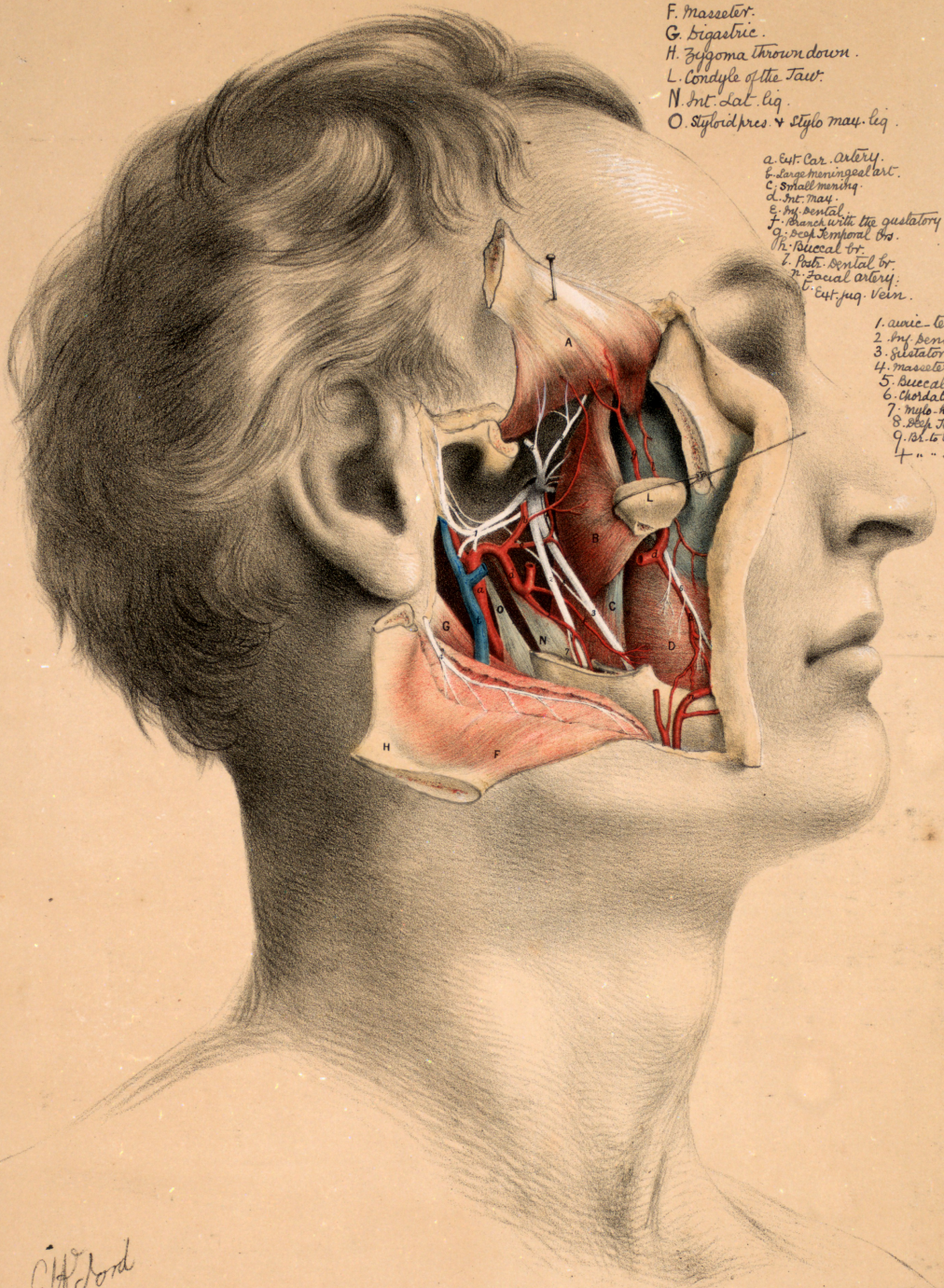

E. H. Ford

from a dissection by G. V. Ellis

London, Published September 1. 1864

Printed in Colours by W. West.

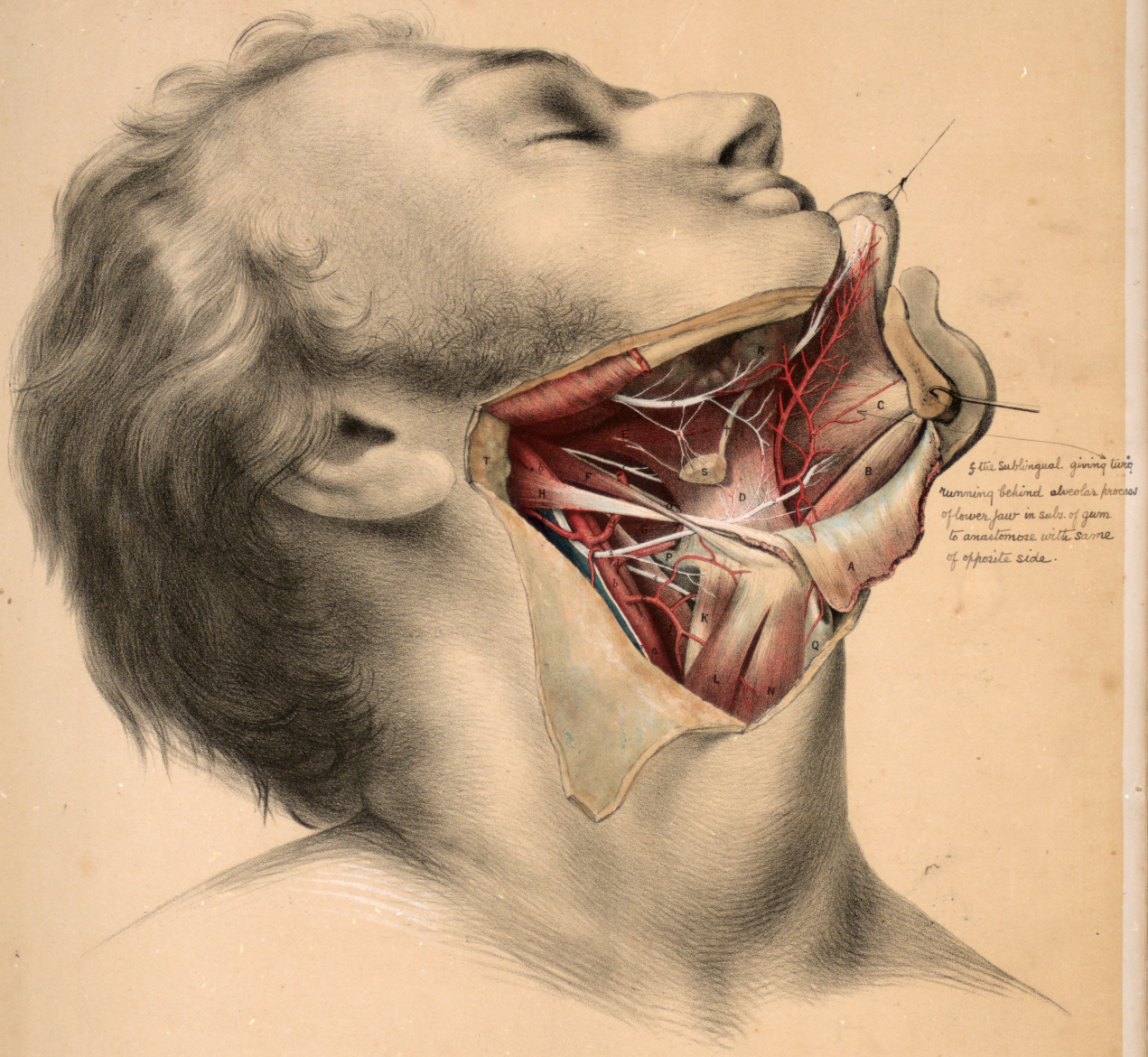

A. Mylo-hyoid (reflected)
B. Genio-hyoid.
C. Genio-glossus.
D. Hyo-glossus.
E. Stylo-glossus.
F. Stylo-hyoid.
G. Middle Constrictor.
H. Digastric.
J. Inf.r Constrictor.
K. Thyro-hyoid.
L. Omo-hyoid.
N. Sterno-hyoid.
O. Stylo-hyoid lig.
P. Great Cornu of Hyoid bone.
Φ Thyroid Cart.

R. Subling. gld.
S. Piece of the Submax. gld.
T. Part of the Parotid gld.
+ Wharton's duct.

a. Common Carotid Artery.
b. External " "
c. Upper thyroid br.
d. Lingual artery
e. Ranine branch.
f. Subling. br.
g. Facial artery (cut.)
h. occipital artery
i. br. of Sublingual art.
l. Int. jug. vein.

1. Glosso-pharyng. n.
2. Hypoglossal n. courses with the lingual artery as far as hyoglossus.
3. Descendens Noni n.
4. upper Laryng. n.
5. Gustatory n.
6. Submax. Ganglion.
7. Loop between the gustatory & hypoglossal nerves.

From a dissection by G.V. Ellis.

London, Published September 1. 1864.

Printed in Colors by W. West.

A. Ext. Pterygoid m.
B. Masseter muscle.
C. Buccinator muscle.
D. Lev. ang. Oris.
E. Lev. Labii Super.
F. Lev. Labii Super. alæque nasi.
G. Orbic. Palpebr.
H. Sup. Rect. Oculi.
I. Maxillary Antrum.
L. Inf. Obliquis Oculi.

a. Int. Max. artery.
b. Poste. Dental branch.
c. Infra orbital br.
d. Buccal br.
e. Int. Carotid artery in Skull.
f. Ophthalmic artery
g. Ext. Carotid trunk.
h. Superfic. Temporal br.
n. Facial n. facial br.

1. Poste. dental br.
2. Supr. Max. n.
3. Optic nerve.
4. Orbital br. cut.
5. Ophthalmic trunk.
6. Inf. Max. trunk.
7. Buccal branch.
8. ant. dental branch.
9. Branches of the facial nerve.

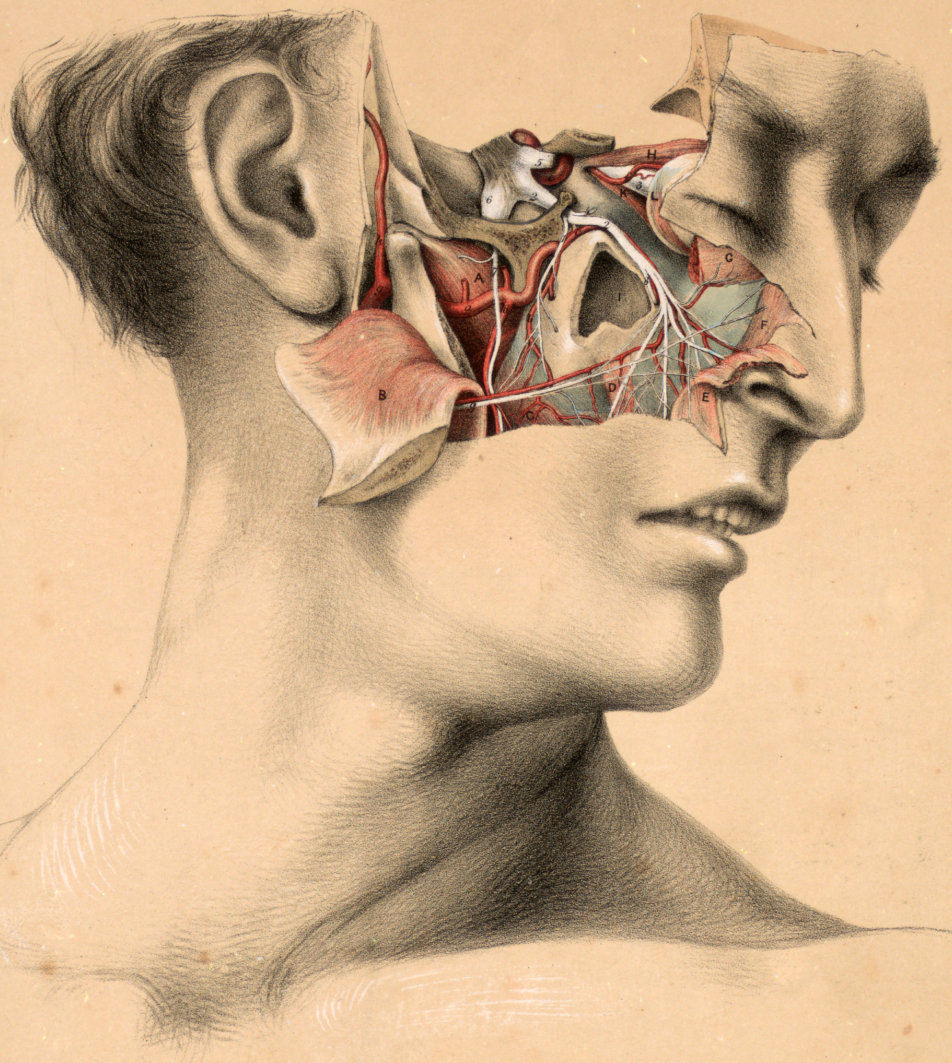

E. H. Ford

From a dissection by G. V. Ellis.
London. Published November 1. 1864.
Printed in Colours by W. West.

For dissection see p. 195.

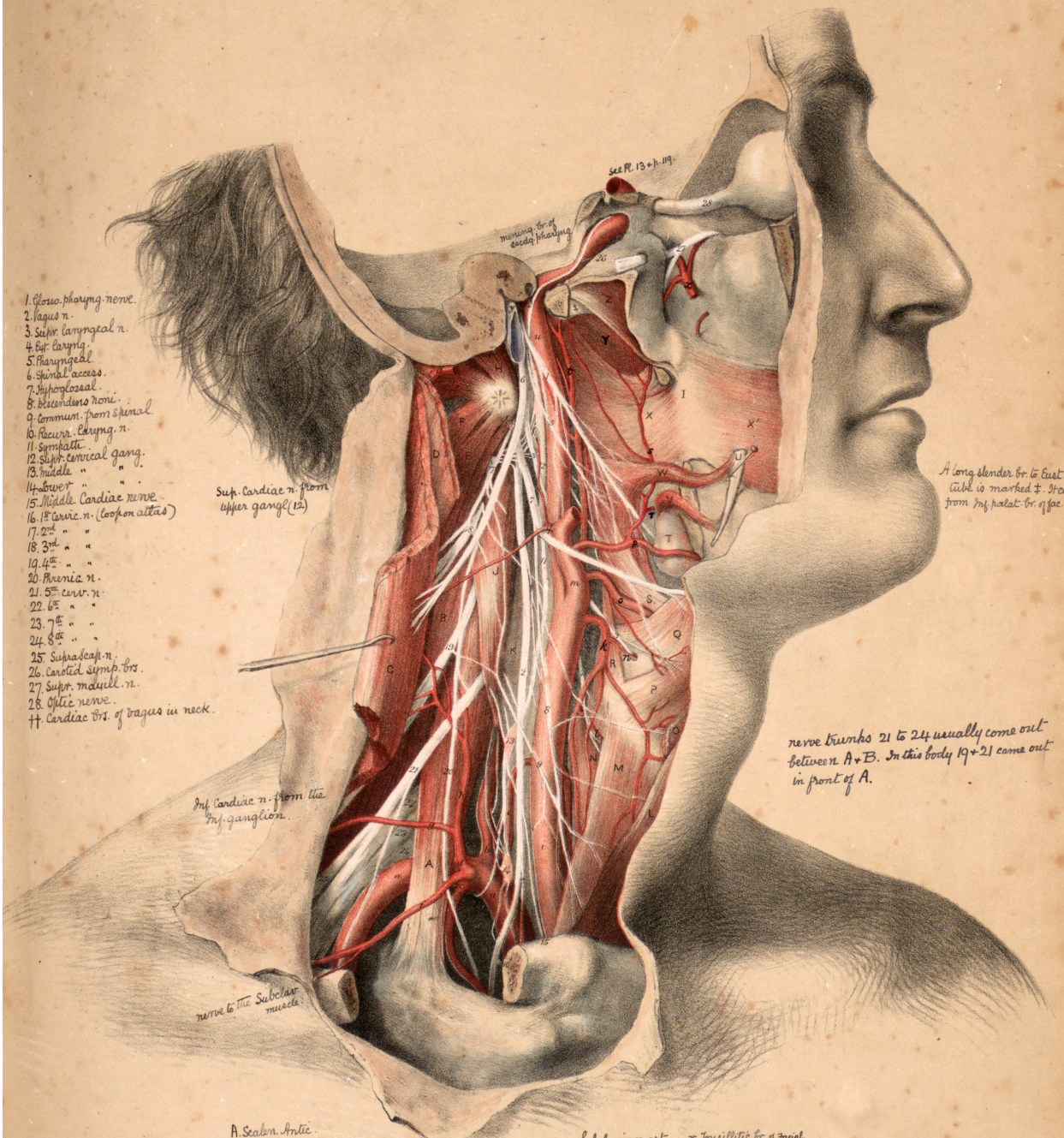

A. Scalen. Antic.
B. Scalen. medius.
C. Sterno-mastoid.
D. Splenius Capitis (cut)
E. Lev. Ang. Scap.
F. Oblig. Inf.
G. Oblig. Super.
H. Rect. Cap. Later.
I. Pterygo-max. ligt.
J. Rect. Cap. antic. major.
K. Long. Colli.
L. Sterno hyoid.
M. Sterno-thyroid.
N. Thyroid body.
O. Omo-hyoid

P. Thyrohyoid
Q. Hyoglossus
R. Inf. Constrictor
S. Middle Constr.
T. Submax. gland.
U. Styloid process (cut off.)
V. Stylo glossus
W. Stylo-pharyngeus
X. Supr. Constrictor.
X' Buccinator.
Y. Lev. Palat.
Z. Tensor Palati
‡ Art. of Eust. tube.

a. Subclavian art.
b. Vertebral art.
c. Int. Mammary.
d. Thyroid axis.
e. Inf. Thyroid.
f. Supra-scapular.
g. Transv. cervic.
h. Ascdg. Cervic.
i. Common Carotid.
k. Supr. Thyroid
l. Crico-thyroid br. of k.
m. Ext. Carotid.
n. Laryngeal br. of Supr. Thyr.
o. Lingual
p. Facial
q. Occipital. cut. br. to Sterno-mastoid.

r. Tonsillitic br. of Facial.
s. Inf. Palatine br. do.
t. Ascdg. Pharyng.
u. Int. Carotid.
x. Int. Maxillary art. (cut.)
y. Int. jug. vein (cut.)

Inf. Thyroid art. here = a rare condition. It arises from the Vertebral (b) artery instead of from d.

Common Carotid here divides higher than usual

Elb Ford

From a dissection by C.V. Ellis.

London, Published November 1, 1864.

Printed in Colours by W. West.

For this dissect see expl. text p. 205.

A. Inf. Constr.
B. Middle Constric.
C. Supr. " .
D. Stylo-pharyngeus.
E. Levator-palati.
F. Tensor palati.
G. Buccinator.
H. Stylo-glossus cut.
I. Temporal muscle.
J. Mylo-hyoid.
K. Sterno ~~thyr~~oid.
L. Omo-hyoid.
M. Hyo-glossus.
N. Thyro-hyoid.
O. Stylo-hyoid lig. ossified
P. Sterno-thyroid
Q. Crico-thyroid
R. Thyroid-thrown down.
S. Oesophagus.
T. Trachea.
†. Pterygo-maxillary lig.

a. Inf. Thyroid artery
b. Laryngeal branch.
c. Thyroid branch.
d. Laryngeal branch of upper Thyroid
e. Lingual artery.
f. Internal Carotid.

1. Glossopharyngeal n.
2. Gustatory nerve.
3. Hypoglossal nerve.
4. Upper laryngeal n.
6. Ext. Laryngeal n.
7. Recurr. Laryngeal nerve.
See Pl. 27.

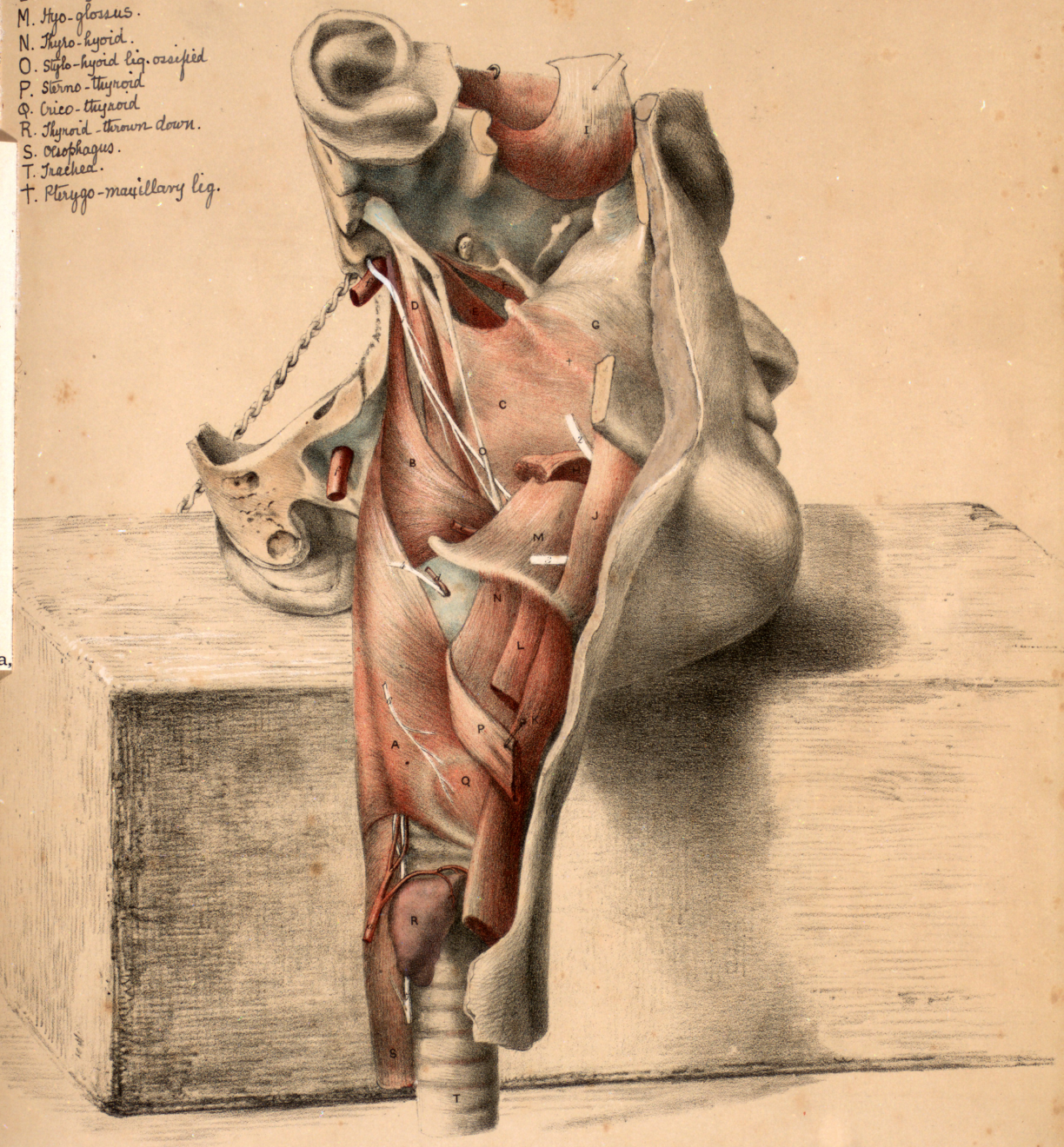

W. Ford

...m a dissection by C.V. Ellis. London, Published Jan. 1, 1865. Printed in Colours by W. West.

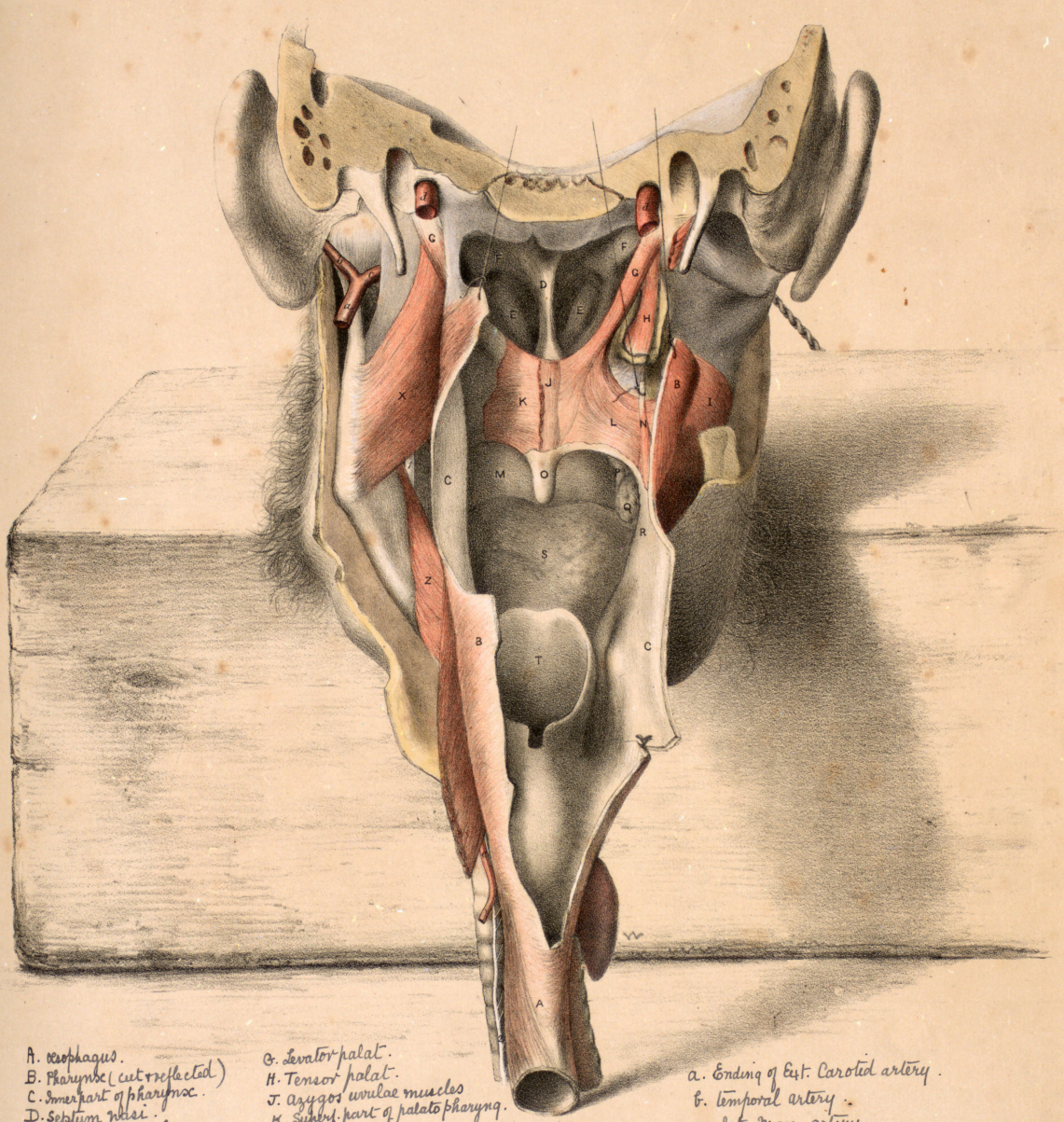

A. œsophagus.
B. Pharynx (cut & reflected)
C. Inner part of pharynx.
D. Septum nasi.
E. Lower spongy bone.
F. Eust. tube.
L. Buccinator muscle.
K. Soft Palate
M. Roof of the Mouth.
N. Salpingo-pharyngeus
O. uvula.
P. ant. pillar of fauces.
Q. The tonsil.
R. Post. pillar of the palate.
S. Tongue.
T. Epiglottis.
V. upper opng. of Larynx.
W. Opening of Oesoph.
X. Int. Pterygoid muscle.
Z. Mylo-hyoid muscle.

G. Levator palat.
H. Tensor palat.
J. Azygos uvulae muscles
K. Superf. part of palato pharyng.
L. Deep. part of " " .

1. Gustatory n.
2. Recc. Laryng. n.

a. Ending of Ext. Carotid artery.
b. temporal artery.
c. Int. Max. artery.
d. Int. Carotid artery.
e. Inf. Laryngeal br.

From a dissection by C.V.Ellis

London, Published Jan 1 1865

Printed in Colours by W.West

FIG. I.

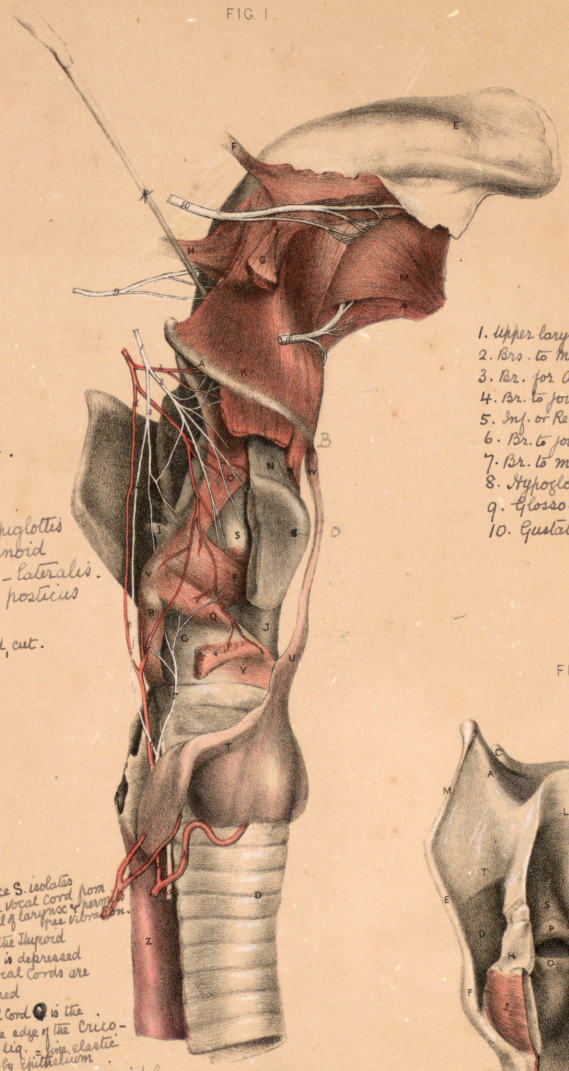

A. Hyoid.
B. Thyroid.
C. Cricoid.
D. Trachea
E. Tongue
F. Palato-Glossus muscle.
G. Stylo glossus
H. Pharyngeo glossus.
I. Cornicula laryngis.
J. Crico-thyroid membr.
K. Hyo glossus muscle.
L. Epiglottis
M. Genio-hyo-glossus.
N. Thyro-hyoid membr.
S. Sacculus laryngis.
T. Thyroid gland.
U. Pyramid of Thyroid
W. Levator glandulae thyroid.
X. Stylo-hyoid liq., ossified.
Z. Oesophagus.

O. Depressor of Epiglottis
P. Thyro-arytaenoid
Q. Crico-aryt.-lateralis.
R. " " posticus
V. Arytaenoid
Y. Crico-thyroid, cut.

a. Upper laryngeal art.
b. ascending br. " .
c. descending br. " .
d. Communicating br. of Sup. L. art.
e. " " " of Infr. L. art.
f. musc. br. " " " " "
g. Inf. Laryngeal artery.
h. Br. of Sup. Thyroid art. to gld.
k. Br. of Infr. " " " "

1. Upper laryngeal n.
2. Brs. to mucus membr.
3. Br. for Arytaenoid.
4. Br. to join Inf. laryngeal.
5. Inf. or Recurrent laryngeal.
6. Br. to join Upper laryngeal.
7. Br. to muscles.
8. Hypoglossal n.
9. Glosso-pharyngeal n.
10. Gustatory n.

FIG. II.

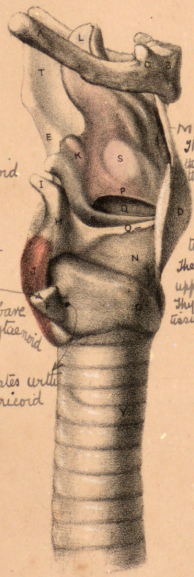

Right half of Thyroid cart. cut away except Fore part & lower cornu

muscles & muc. membr. then taken away to lay bare the Vocal Cord & the Arytaenoid Cartilage of same side.

articulates with the Cricoid

The Space S. isolates the true Vocal Cord from the wall of larynx & permits free vibration.

When the Thyroid Cart. is depressed the Vocal Cords are tightened

The Vocal Cord O is the upper free edge of the Crico-Thyroid liq. = fine elastic tissue cov. by Epithelium.

A. Great Cornu of Hyoid bone.
B. Body of Hyoid bone.
C. Small Cornu do.
D. Thyroid Cart.
E. Upper Cornu of Thyroid.
F. Lower " " " .
G Cricoid Cart.
H. Arytaenoid Cart.
I. Cart. of Santorini
J. Crico-arytaenoid. postic. muscle.
K. Cuneiform Cart.
L. Epiglottis.
M. Thyro-hyoid liq.
N. Crico-thyroid liq.
O. True Vocal cords.
P. False " " .
Q. Ventricle of larynx.
R. Rima Glottidis
S. Sacculus Laryngis.
T. Thyro-hyoid membr.
U. Arytaeno-Epiglottidean fold.
V. Arytaenoideus-postic.
W. Interior of Trachea.
X. Musc. part of " .
Y. Rings of " .

FIG. III.

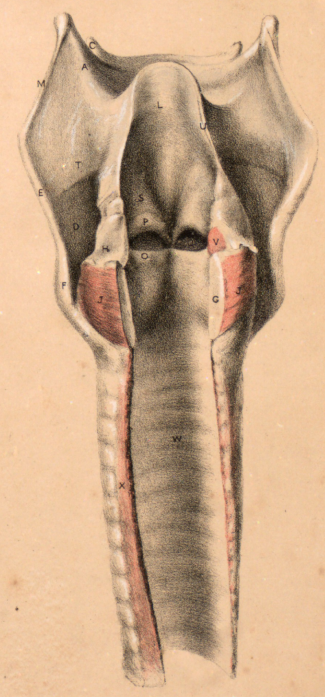

E H Ford

From a dissection by G.V. Ellis.

London, Published Mar. 1, 1865

Printed in Colours by W. West

FIG I.

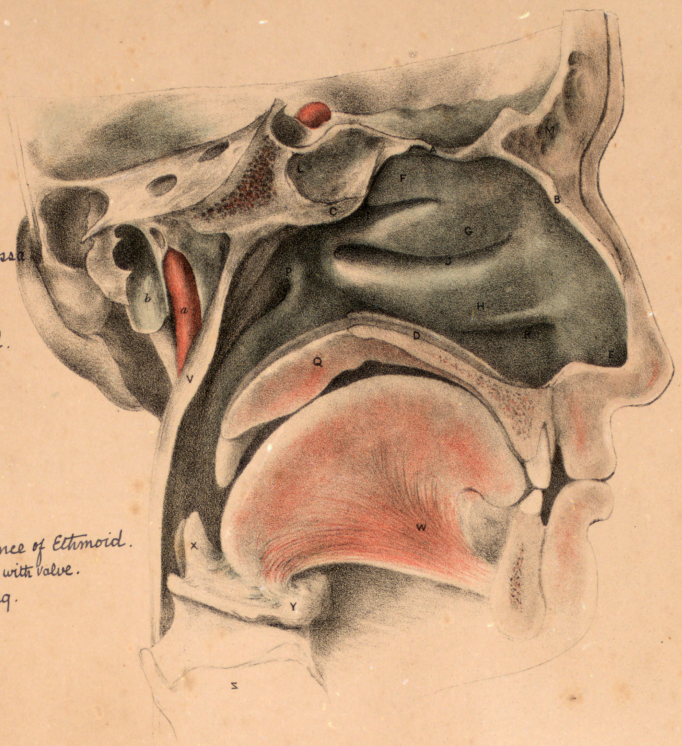

A. Middle part Roof nasal fossa.
B. Fore part do.
C. Back of roof.
D. Floor of n.c.
E. Dilatation within nostril.
F. Upper Spongy bone.
G. Middle " ".
H. Lower " ".
I. Upper meatus of nose.
J. Middle " " ".
K. Lower " " ".
L. Sphenoidal Sinus.
M. Frontal Sinus.
N. Funnel shaped prominence of Ethmoid.
O. Aperture of nasal duct - with valve.
P. Eustachian tube opening.
Q. Soft palate - cut.
R. Descdg. plate Ethmoid.
S. Vomer.
T. Cart. of Septum.
U. " " aperture.
V. Pharynx.
W. Genio-hyo-glossus.
X. Epiglottis
Y. Hyoid bone.
Z. Thyroid Cart.

FIG. II.

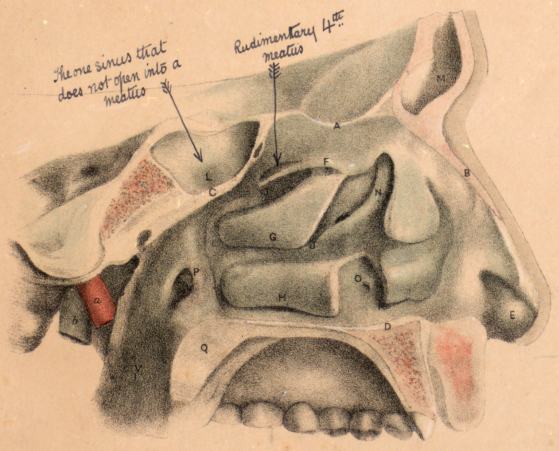

FIG III.

Ed Ford

From a dissection by C V Ellis

London Published Mar 1 1865

Printed in Colours by W West

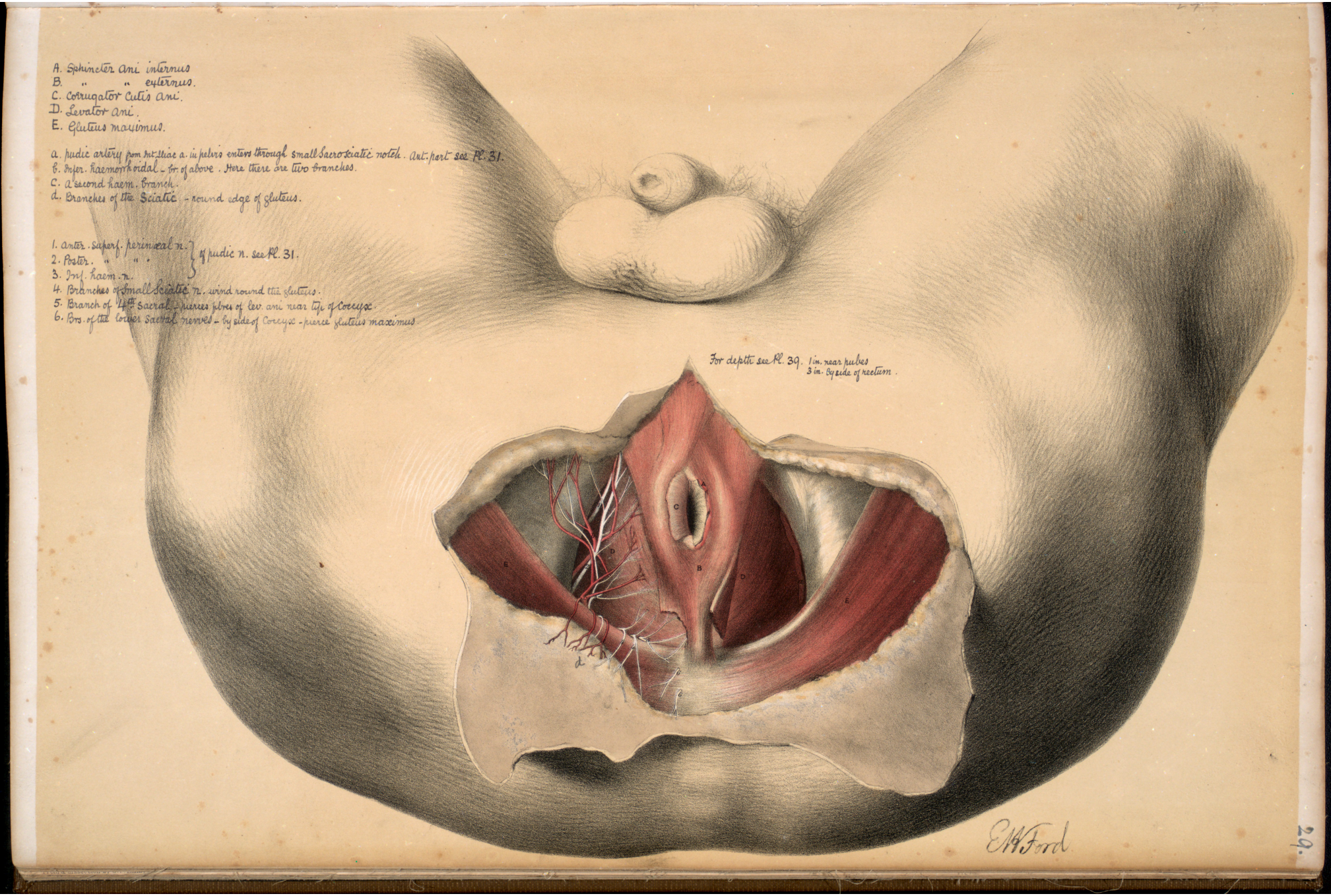
A. Sphincter ani internus
B. " " externus.
C. Corrugator Cutis ani.
D. Levator ani.
E. Gluteus maximus.
a. pudic artery from Int. Iliac a. in pelvis enters through small Sacrosciatic notch. Ant. part see Pl. 31.
b. Infer. haemorrhoidal - br. of above. Here there are two branches.
c. A second haem. branch.
d. Branches of the Sciatic - round edge of gluteus.
1. anter. superf. perinæal n.
2. Poster. " " .
3. Inf. haem. n.
of pudic n. see Pl. 31.
4. Branches of Small Sciatic n. wind round the gluteus.
5. Branch of 4th sacral - pierces fibres of lev. ani near tip of Coccyx.
6. Brs. of the lower sacral nerves - by side of Coccyx - pierce gluteus maximus.
For depth see Pl. 39. 1 in. near pubes
3 in. by side of rectum.
E.H. Ford
29.

G. The Superf. fascia.

In this plate the Superf. layer of muscles only.
3 on each side.

2 of these = C & D. are connected with tube of urethra.
1 " " = F. belongs to the penis.

Note the triangular interval between the muscles.

A. Sphincter ani Externus.
B. Levator ani.
C. Transversalis perinæi.
D. Ejaculator urinæ. covers bulb + 2 inches of urethra.
E. Gluteus maximus.
F. Erector Penis.

a. Superf. perinæal art. from pudic trunk.
b. Transv. " " — from above or from pudic trunk.
c. Cut. offsets of Superf. perin. to the thigh.

1. Inf. haem. n. br of pudic nerve.
2. Poste. of the two Superf. perinæal ns. also the more superficial.
3. Anter. " " " " " . passes generally under the transv. muscle } from pudic n.
4. Inf. pudendal nerve - abr. of small Sciatic.

Central point of the perinæum
½ in. in front of anus.

E. A. Ford.

A. Sphincter ani Exter.
B. Lev. ani
C. Bulb of Urethra.
D. Ejaculator urinae _ cut.
E. Gluteus maximus.
F. Erector Penis
G. Crus Penis _ cut.
H. Constrictor Urethræ.
J. Deep Transv. muscle. not always separate from H.
K. Triang. lig.

Trunks of Pudic artery + n. delineated on left side
distrib. of deep musc. brs. on the other.

a. Pudic artery in Ischio rectal fossa.
b. " " in Triang. lig. more or less cov. by fibres of Constrictor urethræ.
c. Dorsal artery of penis
d. Superf. perinaeal, cut.
e. Deep transv. perinaeal br.
f. Br. to Corp. Spongios.
n. Artery of the Bulb.

(n.) a large perinaeal br. of pudic nerve
splits into two superf. perinaeal n's.
The deep branches come from the deeper of the two
4. pierces the triang. lig. + ends in H.
+ in this body the same br. supplied F.
5. br. enters Corp. Spong. Urethræ.

Encircling the Urethral tube within fibres of Constrictor is a thin layer of circ. involunt. musc. fibres, continuous behind with the fibres of the Prostate.

Triang. lig. length from above down = $1\frac{1}{2}$ inches.

It closes the interval between the contiguous borders of the levatores ani.

Postr. layer of - is continuous with pelvic fascia.
See Pl. 39.

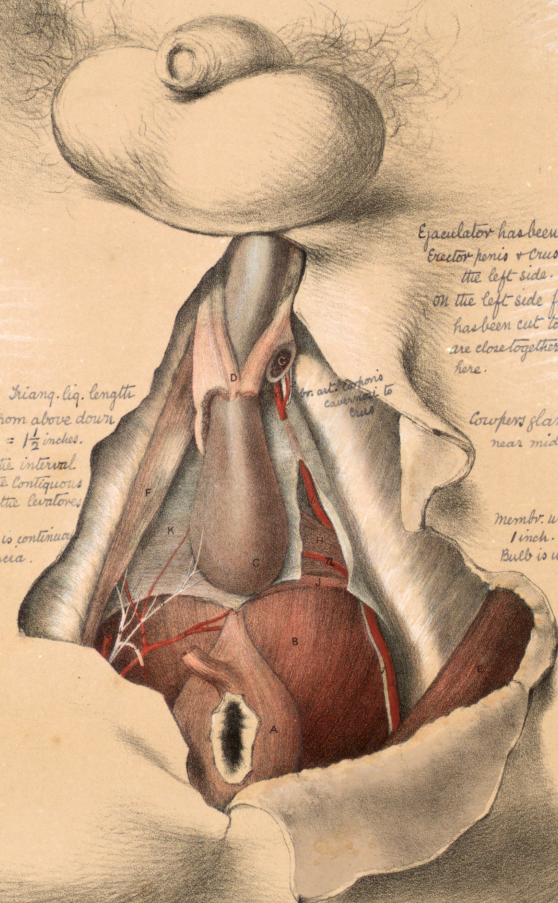

br. art. Corporis cavernosi to Crus

Ejaculator has been removed see pl. 30.
Erector penis + Crus penis detached from bone on the left side.
On the left side fore part layer of Triang. lig. has been cut to show structures between. The two layers are close together above but widely separated below as seen here.

Cowpers glands lie under J + H. muscles near middle line - below urethra.

Membr. urethra rather less than 1 inch.
Bulb is united to front of triang. lig by fibrous tissue.

Ed. Ford

From a dissection by G. V. Ellis

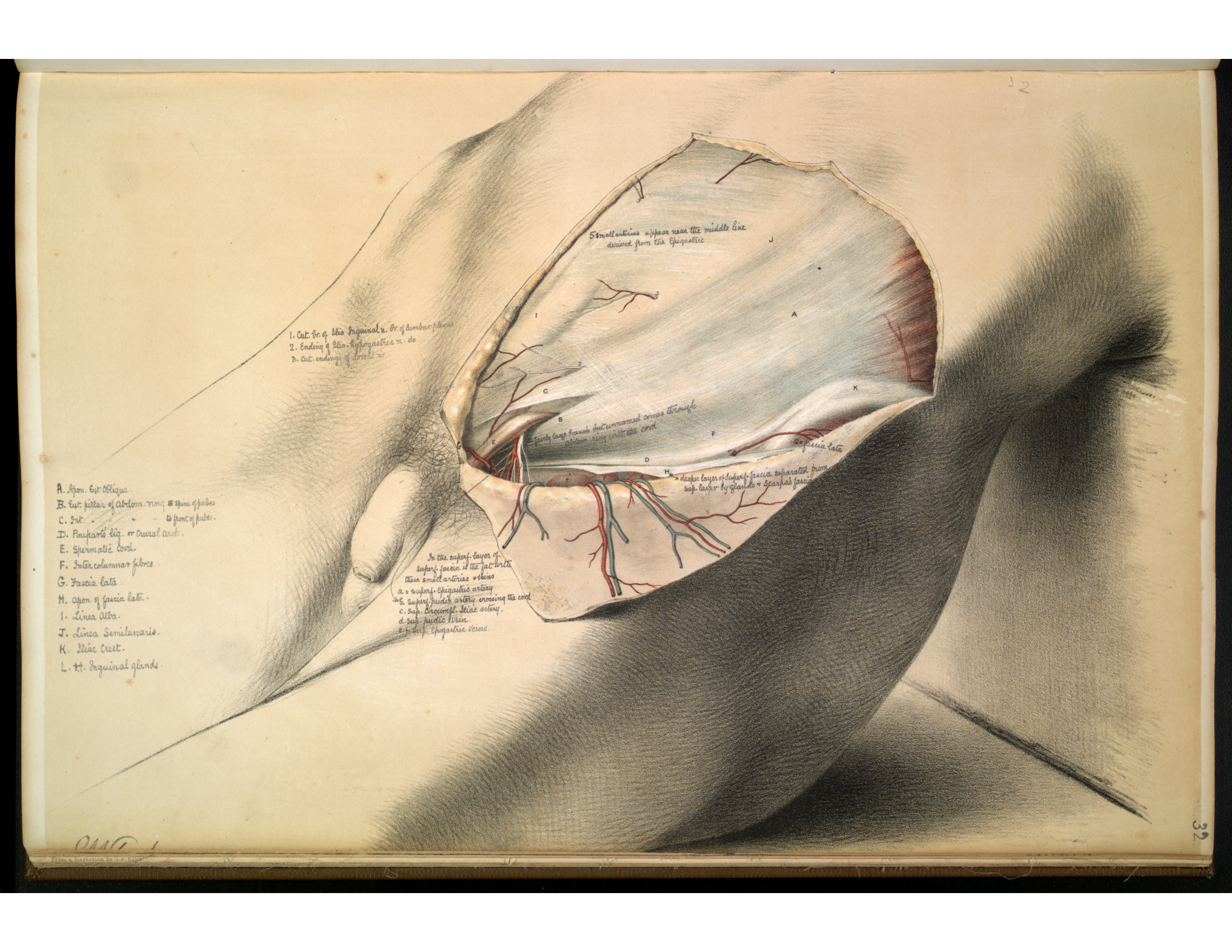

From a dissection by G. V. Ellis.

32

A. Ext: Oblique
B. Tendon of Oblique reflected.
C. Pouparts Lig.
D. Cremaster muscle.
E. Pyramidalis muscle.
F. Spermatic Cord.
G. Int. Oblique.
I. Band behind Pouparts Lig.

1. Ilio hypogastric n. from lumbar plexus. for end in integ. Pl. 32. f. 267.
2. Ilio inguinal n.
3. Cremasteric branch.
4. Br. to pyramidalis muscle.
5. Offsets of a dorsal nerve.

33.

E. A. Ford

From a dissection by G. V. Ellis.

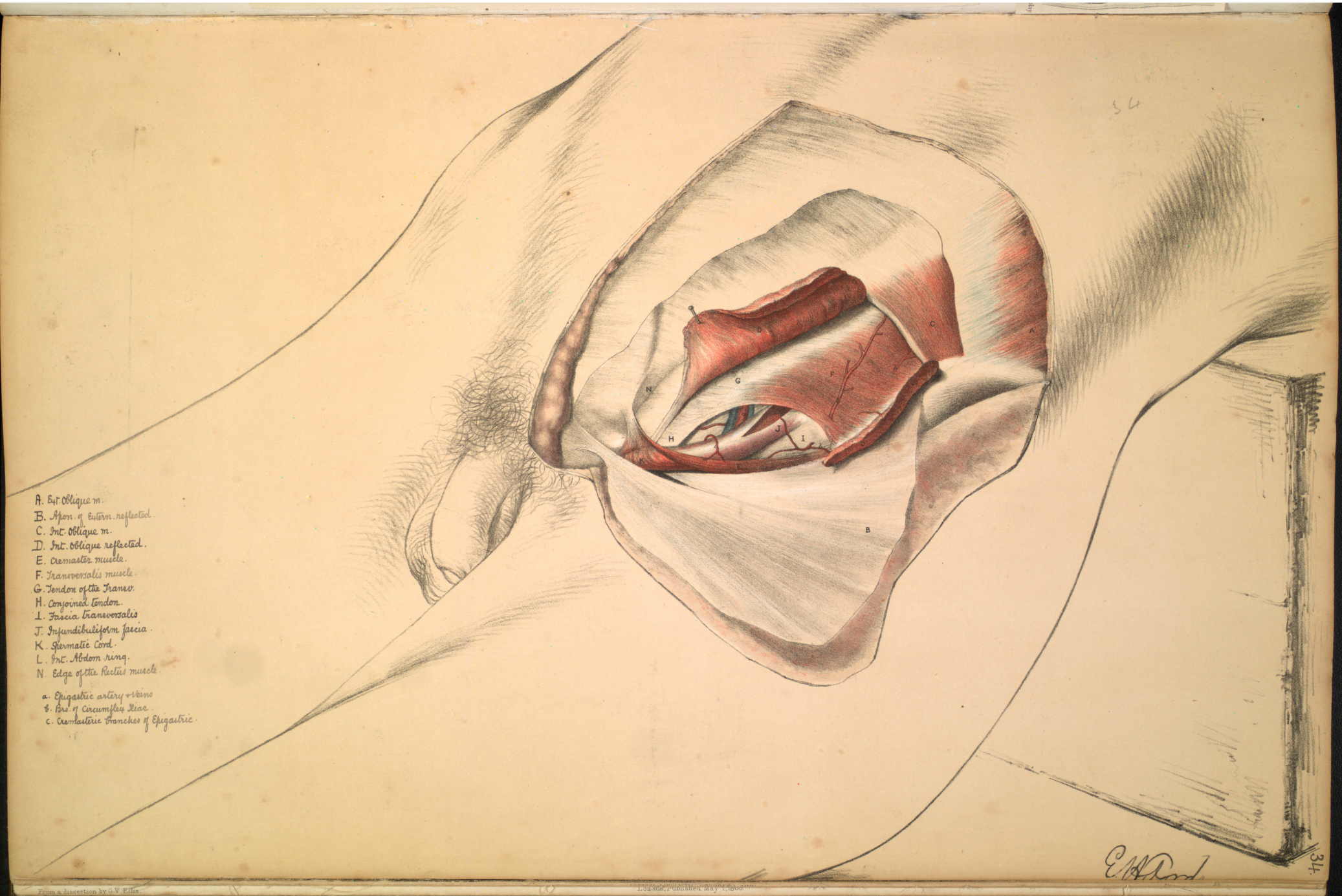

A. Ext. Oblique m.
B. Apon. of Extern. reflected.
C. Int. Oblique m.
D. Int. Oblique reflected.
E. Cremaster muscle.
F. Tranversalis muscle.
G. Tendon of the Transv.
H. Conjoined tendon.
I. Fascia tranversalis
J. Infundibuliform fascia.
K. Spermatic Cord.
L. Int. Abdom ring.
N. Edge of the Rectus muscle.

a. Epigastric artery & veins
b. Brs. of Circumflex Iliac.
c. Cremasteric branches of Epigastric.

From a dissection by G.V. Ellis.

London, Published May 1, 1866.

34

Lig. of Ext. Iliac Artery.

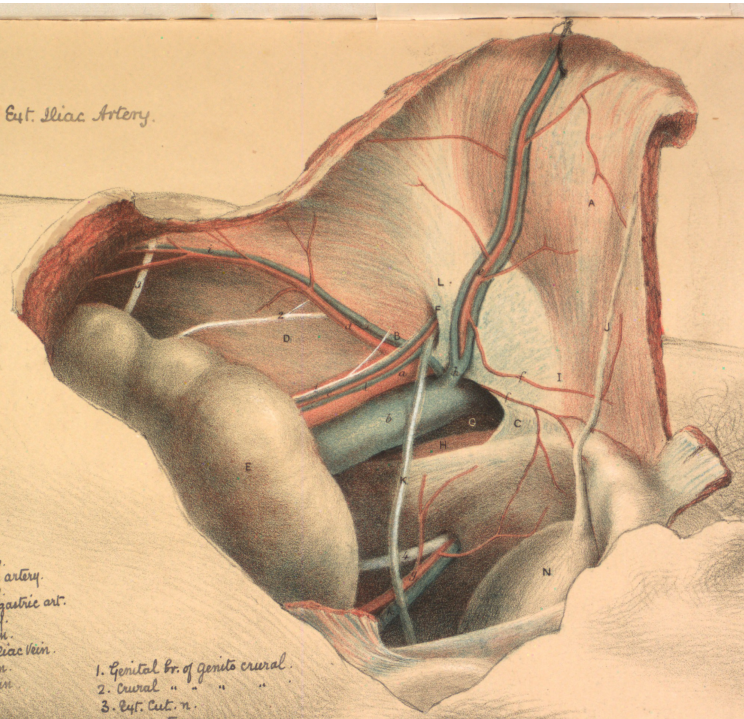

A. Rectus Abdom. under the fascia.
B. Crural arch.
C. Gimbernat's Lig.
D. Iliac fascia.
E. Sigmoid flex. of Colon.
F. Intern. Abdom. Ring.
G. Crural Ring.
H. Pectineus muscle cov. by fascia lata.
I. Inner Inguinal fossa.
J. Urachus of Bladder
K. Vas deferens.
L. Fascia Transversalis
N. Urinary Bladder.

a. Ext. Iliac artery.
b. " " Vein.
c. Spermatic artery.
d. Circumflex Iliac artery.
e. Epigastric artery.
f. Pubic Br. of Epigastric art.
g. Obturator Artery.
h. Epigastric Vein.
i. Circumflex Iliac Vein.
k. Obturator Vein.
l. Spermatic Vein.

1. Genital Br. of genito crural.
2. Crural " " "
3. Ext. Cut. n.
4. Obturator nerve.

From a dissection by G.V. Ellis.

London, Published JANUARY 1, 1866.
London, Published May 1, 1866.

A. Fleshy part of the diaphragm.
B. Mid part of the tendon.
C. Left piece of the tendon.
D. Right piece of the tendon.
E. Right crus.
F. Left crus.
G. Int. arched lig.
H. Ext. Arched lig.
I. Quad. Lumb.
J. Psoas Parvus.
K. Psoas Magnus.
L. Iliacus.
M. Urinary Bladder.
N. Rectum.
O. Vas deferens
P. Left ureter.
Q. Left Kidney.
R. Supra Renal body.
S. Oesophagus - cut.
T. Pectineus muscle.

a. Aorta
b. Common Iliac artery.
c. Int. Iliac art.
d. Ext. "
e. Diaphragmatic art.
f. Coeliac axis
g. Upper mesenteric artery.
R. Renal artery.
i. Spermatic "
j. Supra renal "
k. Inf. mesaraic artery.
l. Lumbar arteries.
n. Middle Sacral artery.
p. Vena Cava Inf.
q. Common Iliac Vein.
R. Ext. Iliac Vein.
s. Lowest Intercos. art.
t. Renal Vein.
u. Supra renal vein.
v. Spermatic Vein.
w. Lumbar Vein.
x. Middle Sacral Vein.
y. Circumflex Iliac artery.
z.

1. Last dorsal nerve.
2. Ilio-hypog. Br.
3. Ilio-inguinal Br.
4. Crural Br. of genito-crural nerve.
5. Genital Br. of do.
6. Ext. Cut. Br.
7. Ant. Crural n.
8. Ending of Phrenic n.

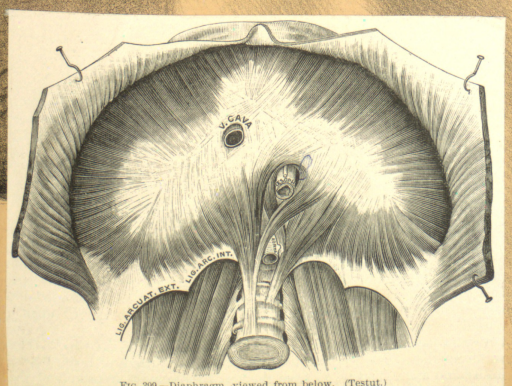

Fig. 399.—Diaphragm, viewed from below. (Testut.)

London Published January 1 1866
London Published May 1 1866
Printed in Colours
Printed in Colours by W. West
From a dissection by G.V. Ellis.

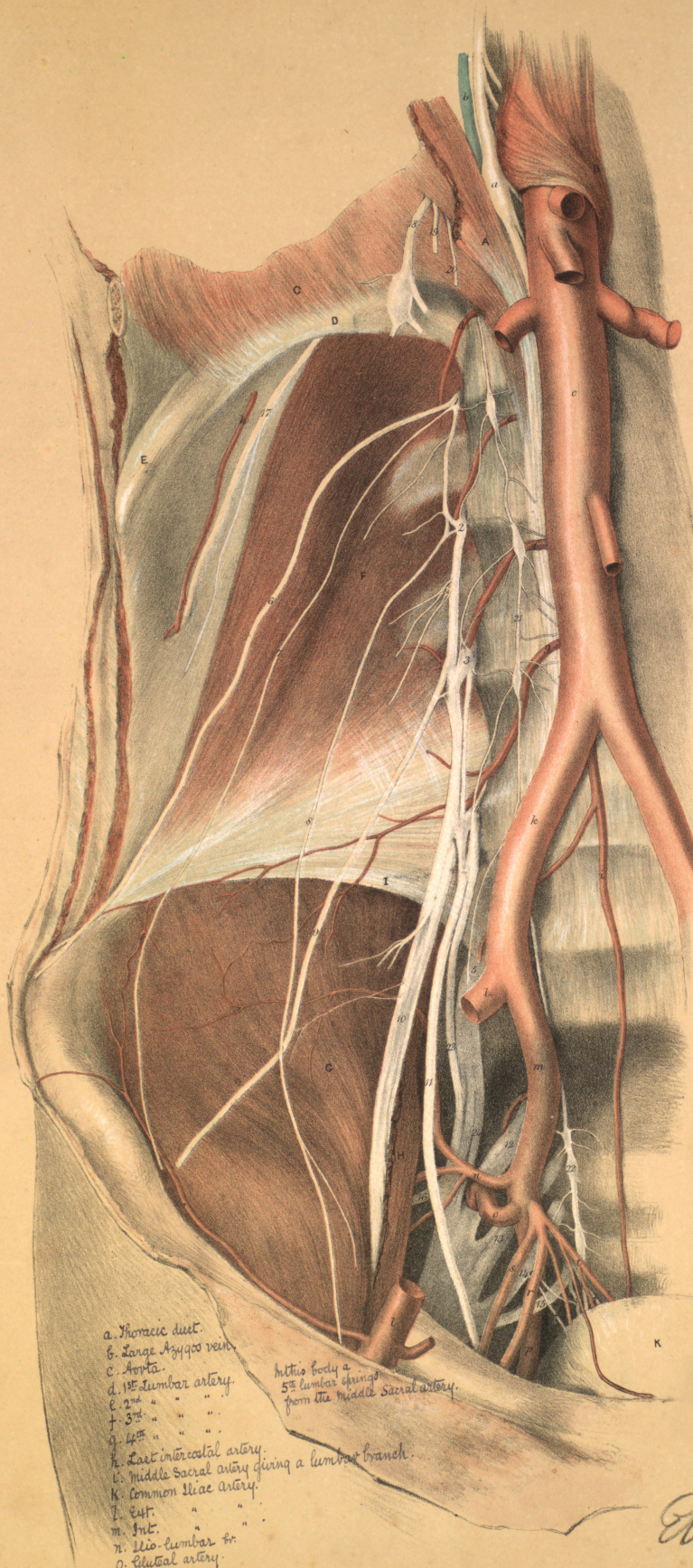

1. 1st lumbar nerve.
2. 2nd " "
3. 3rd " "
4. 4th " "
5. 5th " "
6. Ilio-hypogastric branch.
7. Ilio inguinal branch.
8. Genito Crural branch.
9. Ext. Cutaneous
10. Ant. Crural.
11. Obturator nerve.
12. 1st Sacral nerve.
13. 2nd " "
14. 3rd " "
15. 4th " "
16. Sup. Gluteal branch.
17. Last Dorsal nerve.
18. Great Splanchnic nerve. } Symph.
19. Small. " "
20. Smallest " "
21. Lumbar Ganglia & Cord.
22. Sacral part of the Cord
23. Branch to Lumbo-Sacral
24. Lumbo sacral cord.
25. Sacral plexus.

a. Thoracic duct.
b. Large Azygos vein.
c. Aorta.
d. 1st Lumbar artery.
e. 2nd " " "
f. 3rd " " "
g. 4th " " "
h. Last intercostal artery.
i. Middle Sacral artery giving a lumbar branch.
k. Common Iliac artery.
l. Ext. " "
m. Int. " "
n. Ilio-lumbar br.
o. Gluteal artery.
p. Sciatic branch.
q. Pudic branch.
s. Obturator branch.
t. Visceral Offsets of the Iliac.
v. Lateral Sacral branch.

In this body a 5th Lumbar springs from the Middle Sacral artery.

A. Right crus of diaphragm.
B. Left " " "
C. Fleshy lateral part " ".
D. Ext. Arched lig.
E. 12th rib. right.
F. Quad. Lumborum.
G. Iliacus muscle.
H. Psoas muscle cut.
I. Ilio-vert. lig.
K. urinary bladder.

E. H. Ford

For dissection. See p. 304.

From a dissection by C.V.Ellis

London, Published January 1, 1866.

Printed in Colours by W. West.

Printed in Colours

London, Published January 1, 1866

From a dissection by C.V. Ellis.

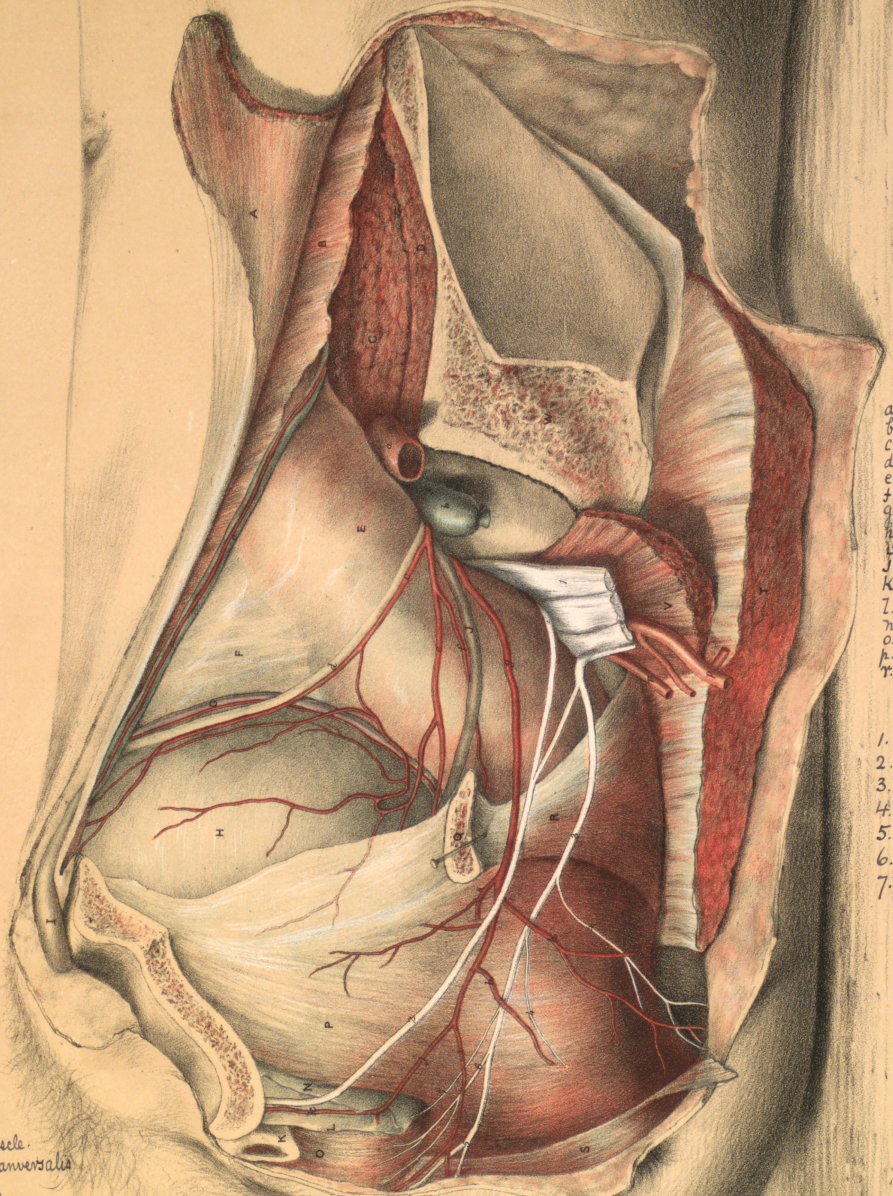

a. Common Iliac artery.
b. " " Vein.
c. Supr. Vesical artery.
d. Obtit. Hypogastric.
e. Middle Vesical artery.
f. Inf. Vesical artery.
g. Pudic artery.
h. Inf. haemorrhoidal br.
i. Superf. perinæal br.
J. & Dorsal artery of Penis.
K.
l. Artery of the bulb.
m. Spermatic artery.
o. Spermatic Veins.
p. Sciatic artery cut.
r. Br. of Sciatic.

1. Sacral plexus.
2. Dors. n. of penis.
3. Perinæal nerve.
4. Inf. Haemorrhoidal br.
5. Superf. perinæal branches.
6. Br. to Epac. urinæ.
7. " " Constrictor urethræ.

A. Ext. Oblique muscle.
B. Int. " + Transversalis
C. Psoas Magnus.
D. Iliacus muscle.
E. Rectum.
F. Peritoneum.
G. Vas deferens.
H. Urinary Bladder.
I. Spermatic Cord.
J. Ureter.
K. Crus Penis. cut through.
L. Ant. & Layers of Triang. Lig.
N. Post. }
O. Ejaculator Urinæ muscle.
P. Levator Ani muscle.
Q. Ischial Spine - Cut off.
R. Coccygeus muscle.
S. Sphincter Ani Ext.
T. Gluteus Max.
V. Pyriformis muscle.
W. Hip Bone - cut.

For this dissection see p. 312.

From a dissection by G.V. Ellis. London. Published January 1, 1866. Printed in Colours
From a dissection by G.V. Ellis. London. Published May 1, 1866. Printed in Colors by W. West

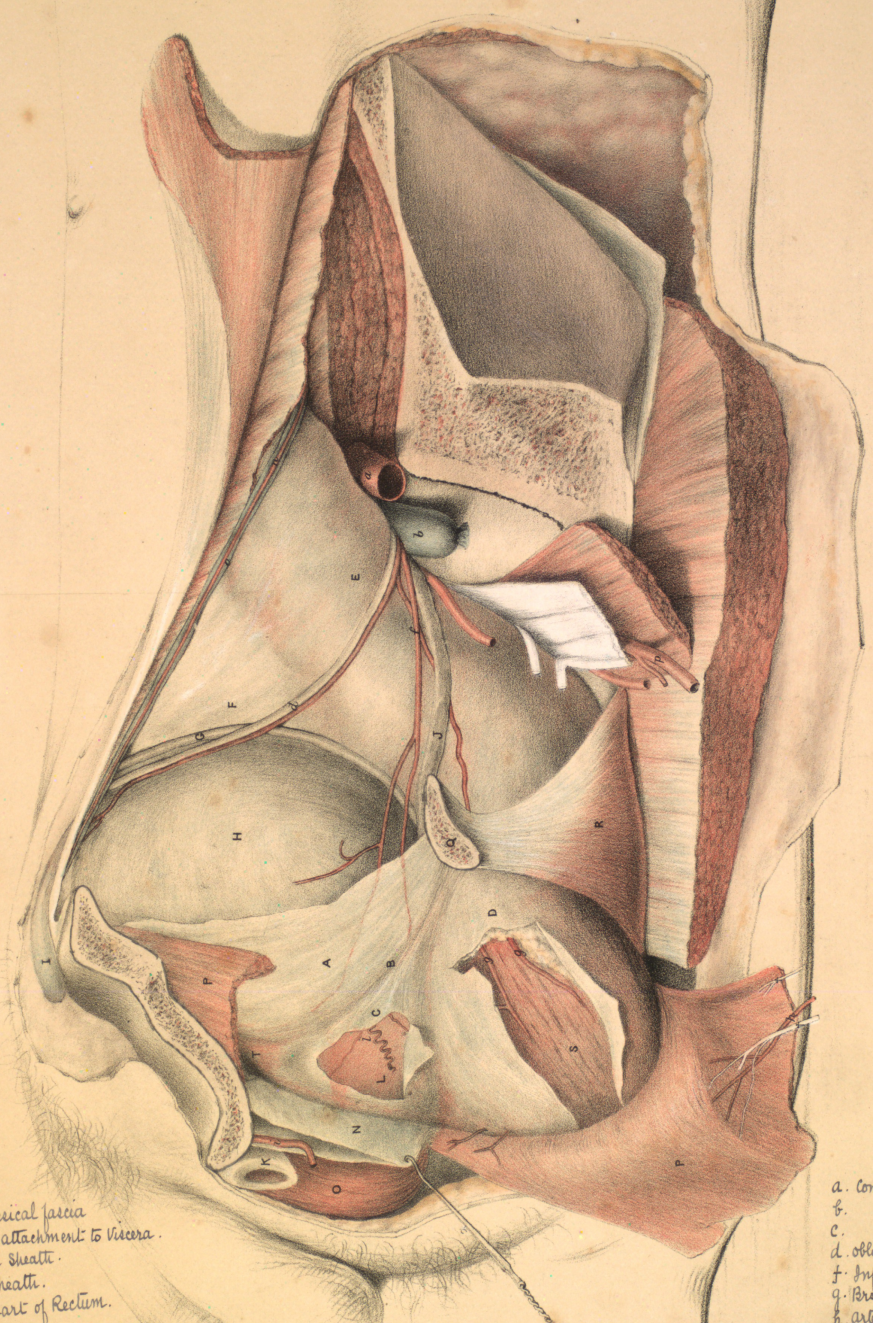

A. Recto Vesical fascia
B. Line of attachment to Viscera.
C. Prostatic Sheath.
D. Rectal Sheath.
E. Upper part of Rectum.
F. Peritoneum.
G. Vas deferens.
H. Urinary Bladder.
I. Spermatic Cord.
J. Ureter
K. Crus penis.
L. Prostate.
N. Triang. lig.
O. Ejac. Urinæ.
P. Levator Ani thrown down.
Q. Ischial Spine - cut off.
R. Coccygeus muscle.
S. Rectum. lower part.

a. Common Iliac artery
b. " " Vein.
c.
d. obliterated hypogastric.
f. Inf. Vesical.
g. Brs. of upper haemorrhoidal.
h. artery to Lev. Ani - cut.
i. Dorsal artery of the penis
l. Prostatic artery.
m. Spermatic artery.
o. " Veins.
p. Sciatic artery.
tt. Nerve to Levator ani cut through.

From a dissection by G. V. Ellis.
London. Published May 1, 1866
Printed in Colors by W. West

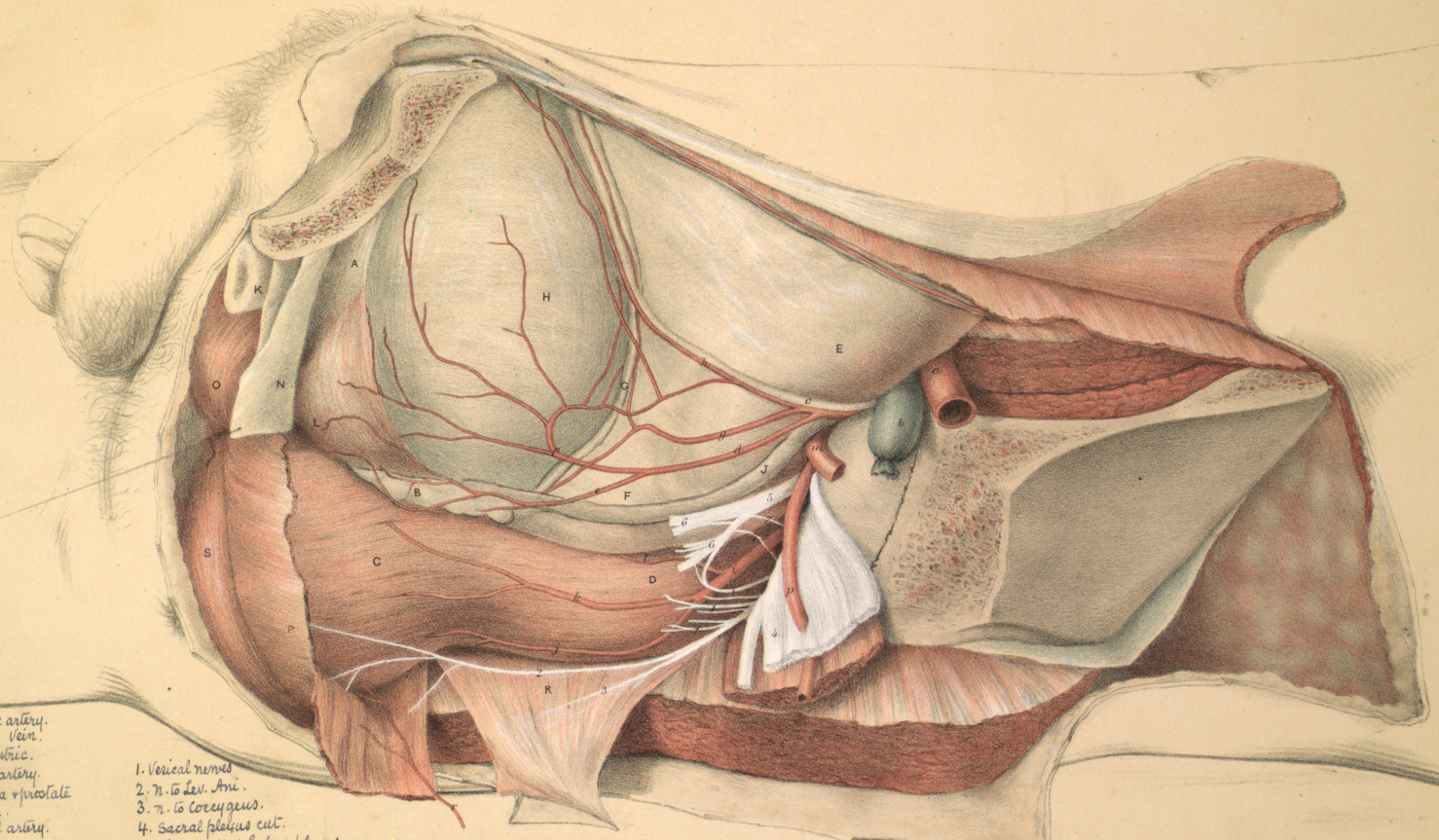

A. Ant. true lig. of bladder.
B. Vesicula Seminalis.
C. Lower part of Rectum.
D. Middle " " "
E. Upper " " "
F. Pouch of peritoneum.
G. Vas deferens
H. urinary Bladder.
J. Ureter.
K. Crus penis - cut.
L. Prostate.
N. Triang. lig.
P. Lev. ani. cut.
R. Coccygeus.
S. Sphincter Ani Extern.

a. Common Iliac artery.
b. " " Vein.
c. Obtt. hypogastric.
d. Inf. Vesical artery.
e. Br. to Vesicula v prostate
f. Br. to Bladder.
g. Middle Vesical artery.
h. Upper " " .
i. Upper haem. artery.
j. } Brs. of do.
k. }
l. }
m. Gluteal artery. cut.
p. Sciatic " " "
r. Br. to Lev. ani. cut.

1. Vesical nerves
2. N. to Lev. Ani.
3. n. to Coccygeus.
4. Sacral plexus cut.
5. Left part of hypog. plexus.
6. Part of Pelvic plexus.
7. Offsets of the Knotted Cord of the Symp. to hypogastric plexus.

G. H. Ford

From a dissection by G.V. Ellis.
London, Published May 1, 1866.
Printed in Colors by W. West

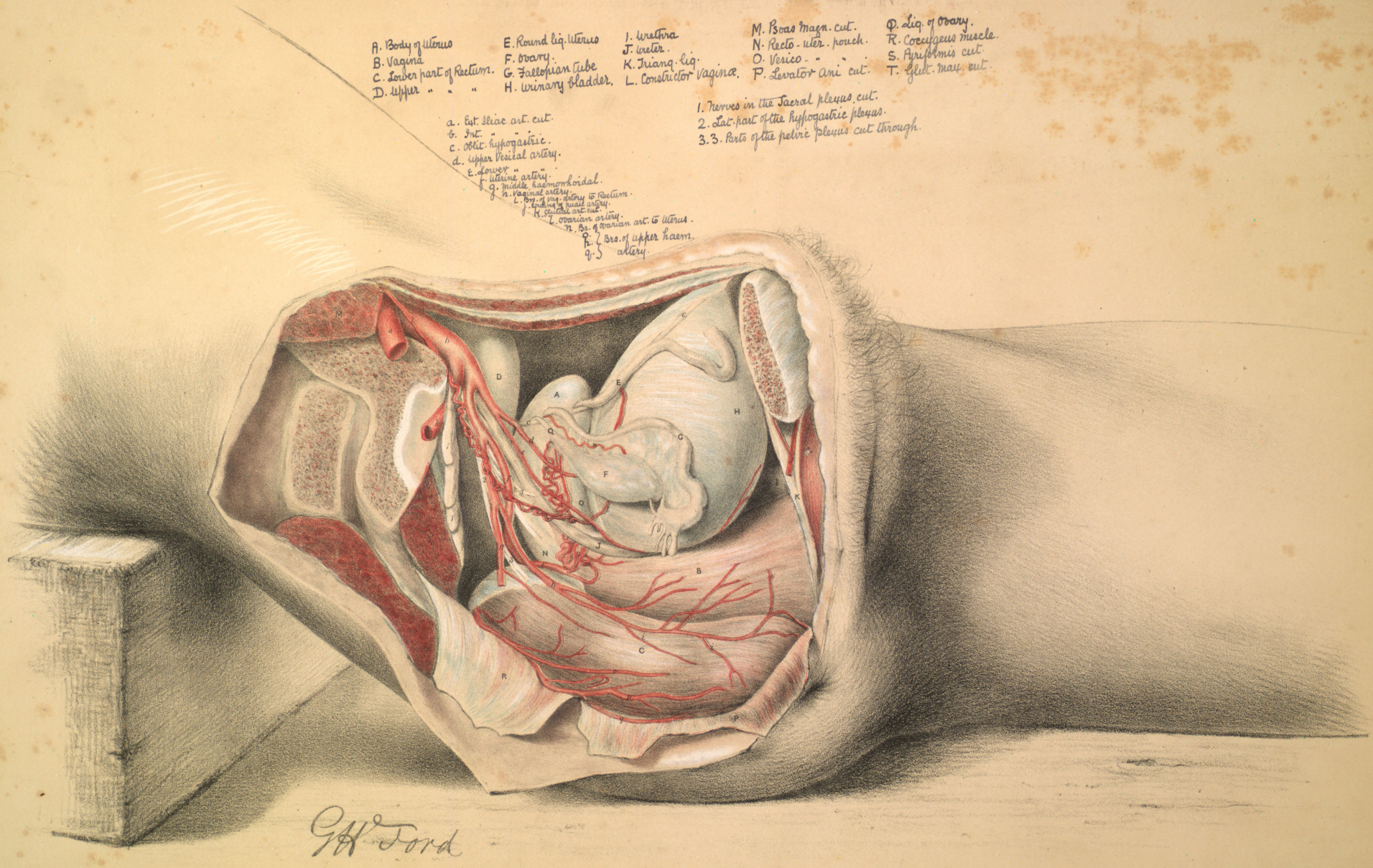

From a dissection by G.V. Ellis.

London, Published May 1, 1866.

Printed in Colors by W. West

41.

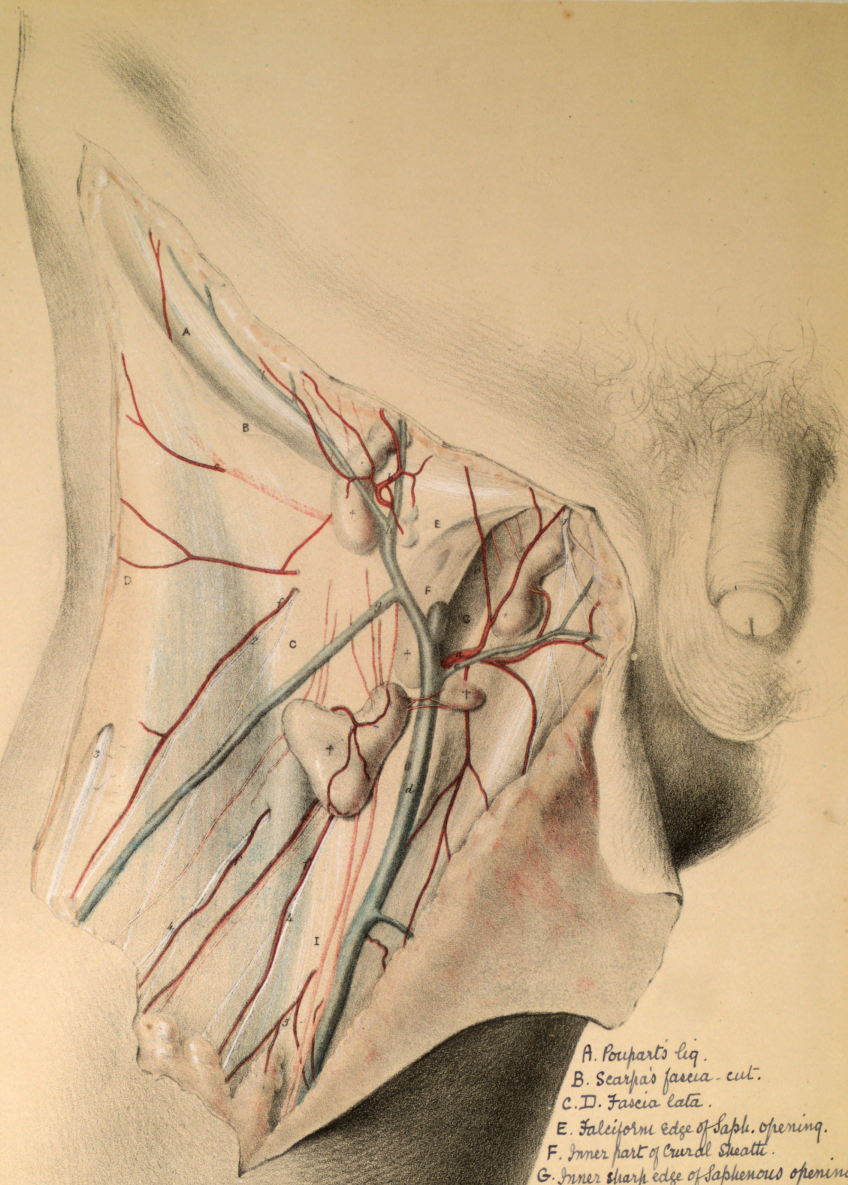

A. Poupart's lig.
B. Scarpa's fascia - cut.
C.D. Fascia lata.
E. Falciform edge of Saph. opening.
F. Inner part of Crural Sheath.
G. Inner sharp edge of Saphenous opening.
H. Saphenous Opening.
I. Opaque line of blood vessels under the fascia.
††. Superf. Inguinal glands.

a. Sup. pudic artery.
b. Sup. Epigastric " .
c. Sup. Circ. Iliac " .
d. Saphenous Vein.
E. Superf. pudic Veins.
f. Cut. Arts. of thigh.
g. Cut. Vein of front of thigh.
h. Superf. Epigastric Vein.
I. Superf. Circ. iliac Vein.

1. Ilio inguinal n.
2. Crural Br. of Genito-crural.
3. Ext. Cut.
4. Middle Cut.
5. Br. of Int. Cut.

G.V. Ford

From a dissection by G.V. Ellis. London, Published May 1. 1866. Printed in Colours by W. West.

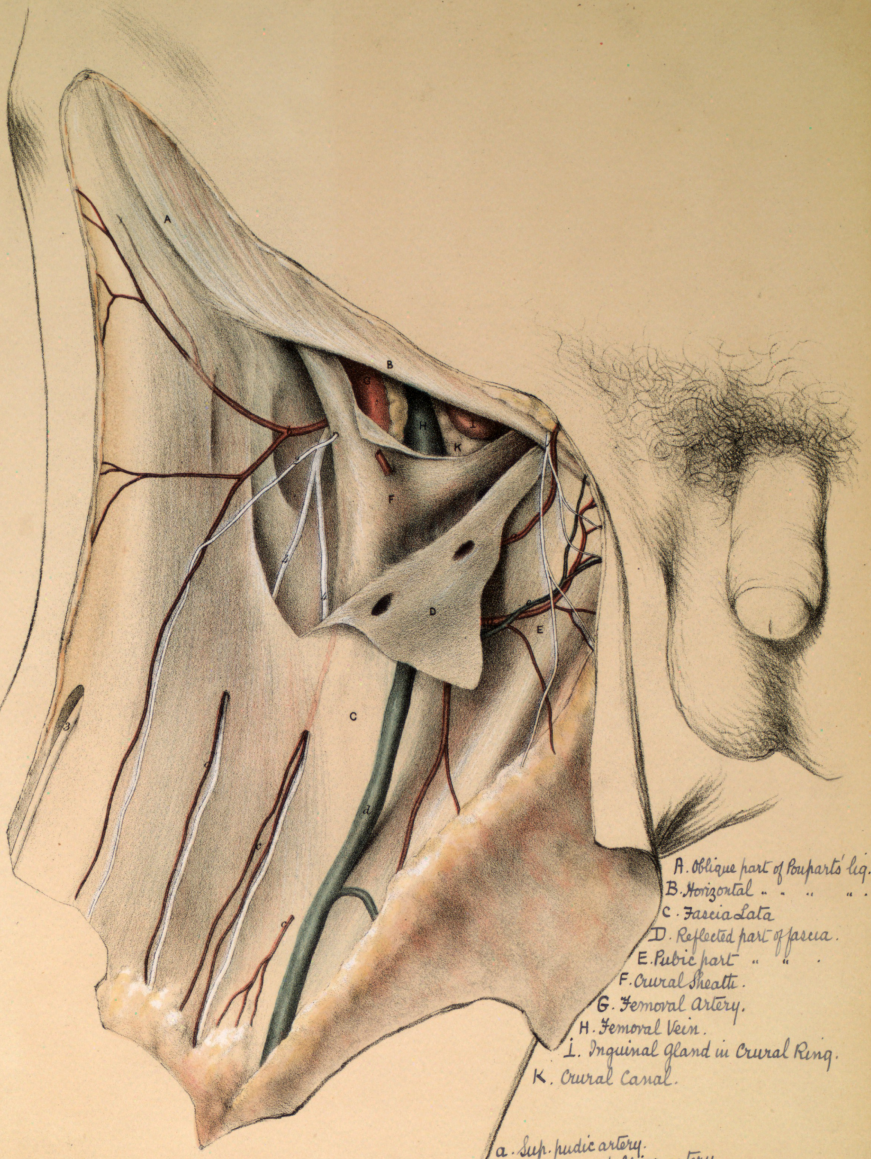

A. Oblique part of Poupart's lig.
B. Horizontal " " " "
C. Fascia Lata
D. Reflected part of fascia.
E. Pubic part " "
F. Crural Sheath.
G. Femoral Artery.
H. Femoral Vein.
I. Inguinal Gland in Crural Ring.
K. Crural Canal.

a. Sup. pudic artery.
b. Sup. Circumf. Iliac artery.
c. Cut. arts. of front of thigh.
d. Int. Saphen. Vein.
e. Superf. pudic Vein.

1. Ilio-inguinal n.
2. Crural br. of genito crural.
3. Ext. Cut. of Thigh.
4. Middle " "

G.H. Ford

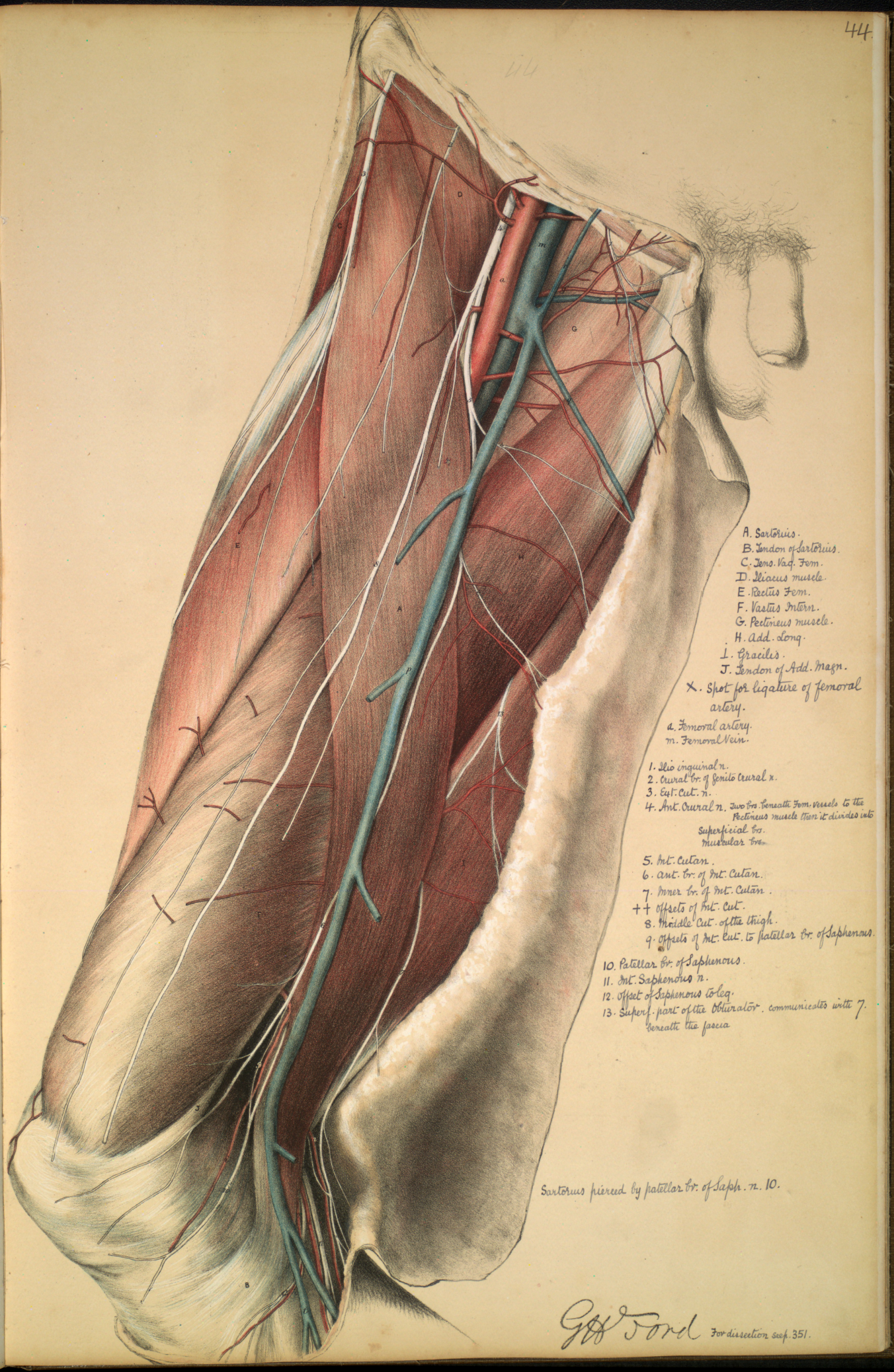

A. Sartorius.
B. Tendon of Sartorius.
C. Tens. Vag. Fem.
D. Iliacus muscle.
E. Rectus Fem.
F. Vastus Intern.
G. Pectineus muscle.
H. Add. Long.
I. Gracilis.
J. Tendon of Add. Magn.
X. Spot for ligature of femoral artery.

a. Femoral artery.
m. Femoral Vein.

1. Ilio inguinal n.
2. Crural br. of Genito Crural n.
3. Cut. Cut. n.
4. Ant. Crural n. Two brs. beneath Fem. vessels to the Pectineus muscle then it divides into Superficial brs. Muscular brs.
5. Int. Cutan.
6. ant. br. of Int. Cutan.
7. Inner br. of Int. Cutan.
++ Offsets of Int. Cut.
8. Middle Cut. of the thigh.
9. Offsets of Int. Cut. to patellar br. of Saphenous.
10. Patellar br. of Saphenous.
11. Int. Saphenous n.
12. Offset of Saphenous to leg.
13. Superf. part of the Obturator. communicates with 7. beneath the fascia.

Sartorius pierced by patellar br. of Saph. n. 10.

G. W. Ford

For dissection see p. 351.

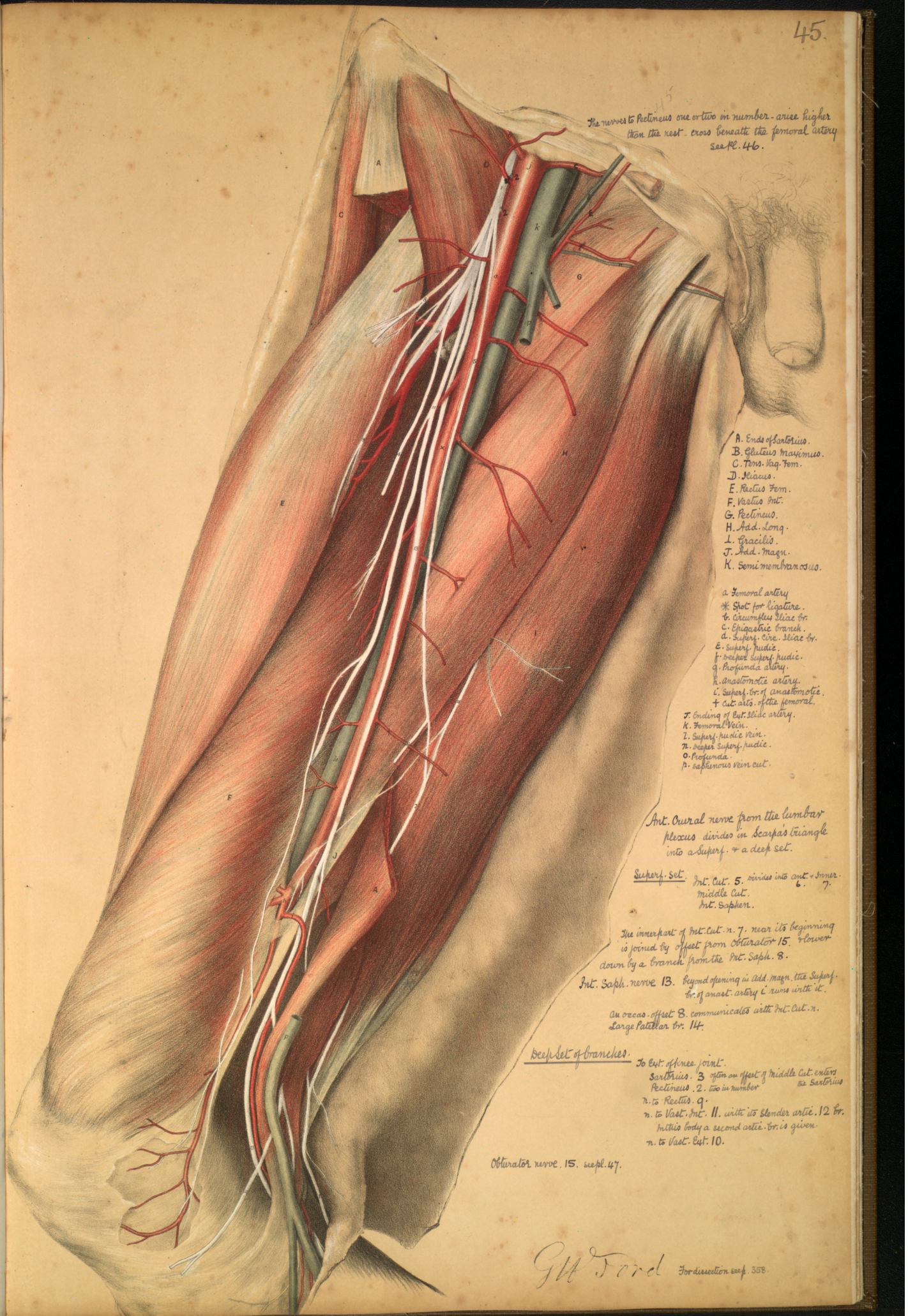

The nerves to Pectineus one or two in number - arise higher than the rest - cross beneath the femoral artery
See Pl. 46.

A. Ends of Sartorius.
B. Gluteus maximus.
C. Tens. Vag. Fem.
D. Iliacus.
E. Rectus Fem.
F. Vastus Int.
G. Pectineus.
H. Add. Long.
I. Gracilis.
J. Add. Magn.
K. Semimembranosus.

a Femoral artery
* Shot for ligature.
b. Circumflex Iliac br.
c. Epigastric branch.
d. Superf. Circ. Iliac br.
e. Superf. pudic.
f. deeper Superf. pudic.
g. Profunda artery.
h. anastomotic artery.
i. Superf. br. of anastomotic.
+ Cut. arts. of the femoral.
J. Ending of Ext. Iliac artery.
K. Femoral Vein.
L. Superf. pudic vein.
m. deeper Superf. pudic.
O. Profunda.
p. saphenous vein cut.

Ant. Crural nerve from the lumbar plexus divides in Scarpa's triangle into a Superf. & a deep set.

Superf. Set. Int. Cut. 5. divides into ant. & inner. 6. 7.
Middle Cut.
Int. Saphen.

The inner part of Int. Cut. n. 7. near its beginning is joined by offset from Obturator 15. & lower down by a branch from the Int. Saph. 8.

Int. Saph. nerve 13. beyond opening in Add. magn. the Superf. br. of anast. artery i runs with it.

An occas. offset 8. communicates with Int. Cut. n.
Large Patellar br. 14.

Deep Set of branches.

To Ext. of knee joint.
Sartorius. 3 often an offset of Middle Cut. enters the Sartorius
Pectineus. 2. two in number
n. to Rectus. 9.
n. to Vast. Int. 11. with its Slender artic. 12 br. Into this body a second artic. br. is given.
n. to Vast. Ext. 10.

Obturator nerve. 15. see pl. 47.

G. H. Ford

For dissection see p. 358.

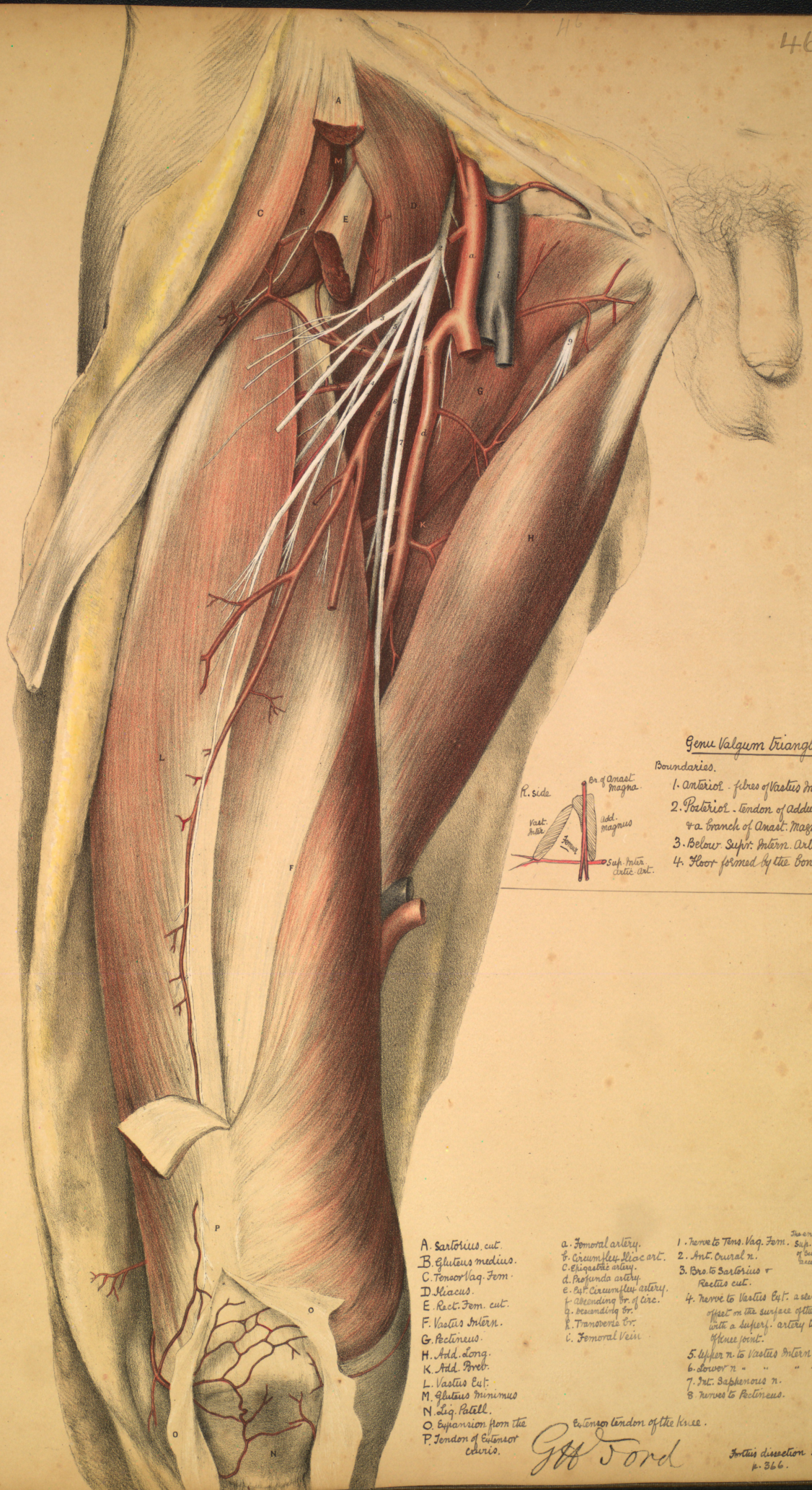

Genu Valgum triangle.

Boundaries.

1. Anterior - fibres of Vastus Internus.
2. Posterior - tendon of Adduct. Magn. & a branch of Anast. Magna.
3. Below Supr. Intern. Artic. artery
4. Floor formed by the Bone.

A. Sartorius. cut.
B. Gluteus medius.
C. Tensor Vag. Fem.
D. Iliacus.
E. Rect. Fem. cut.
F. Vastus Intern.
G. Pectineus.
H. Add. Long.
K. Add. Brevis.
L. Vastus Ext.
M. Gluteus minimus
N. Lig. Patell.
O. Expansion from the
P. Tendon of Extensor cruris.

a. Femoral artery.
b. Circumflex Iliac art.
c. Epigastric artery.
d. Profunda artery.
e. Ext. Circumflex artery.
f. ascending br. of Circ.
g. descending br.
h. Transverse br.
i. Femoral Vein

1. Nerve to Tens. Vag. Fem. The ending of the Sup. Glut. N. w. br. of Sup. Glut. art. accompanies it.
2. Ant. Crural n.
3. Brs. to Sartorius & Rectus cut.
4. Nerve to Vastus Ext. a slender artery runs in the surface of the muscle with a superf. artery to capsule of knee joint.
5. Upper n. to Vastus Intern.
6. Lower n. " " "
7. Int. Saphenous n.
8. Nerves to Pectineus.

P. Tendon of the Knee.

G. H. Ford

For this dissection see p. 366.

For dissect. see p. 371.

A. Sartorius.
B. Psoas muscle.
C. Tens. Vag. Fem.
D. Iliacus.
E. Rectus Femoris (cut.)
F. Vastus Internus.
G. Pectineus (cut.)
H. Adduc. Long. (cut.)
I. Gracilis.
J. Adduct. Magnus.
K. " brevis.
L. Vastus Externus.
M. Semi membranosus.
N. Obturator Externus.
O. Semitendinosus.
P. Int. lat. liq. of knee.

a. Femoral artery.
b. Circumflex iliac
c. Epigastric branch.
d. Prof. or moderately deep femoral.
e. Ext. Circumflex br.
f. Int. Circumflex br.
g. Musc. br. of Circumflex
h. 1st perfor. br.
i. 2nd " " .
j. 3rd " " .
k. Continuation of profunda or 4th perforating
l. anastomotic branch.

1. Ant. & middle cut. (cut). of the thigh.
2. Trunk of Anter. Crural.
3. Nerve of the Rectus (cut.)
4. Nerve to Vastus Externus
5. Upper n. to Vastus Inter.
6. Lower " " " "
7. Int. Saphen. n.
8. Patellar br. of Saphenous.
9. accessory Obturator.
10. Superf. part of Obt.
11. Femoral artery piece too.
12. Piece to join Int. Cut.
13. Deep part of Obtur.
14. Artic. br. of Obturator

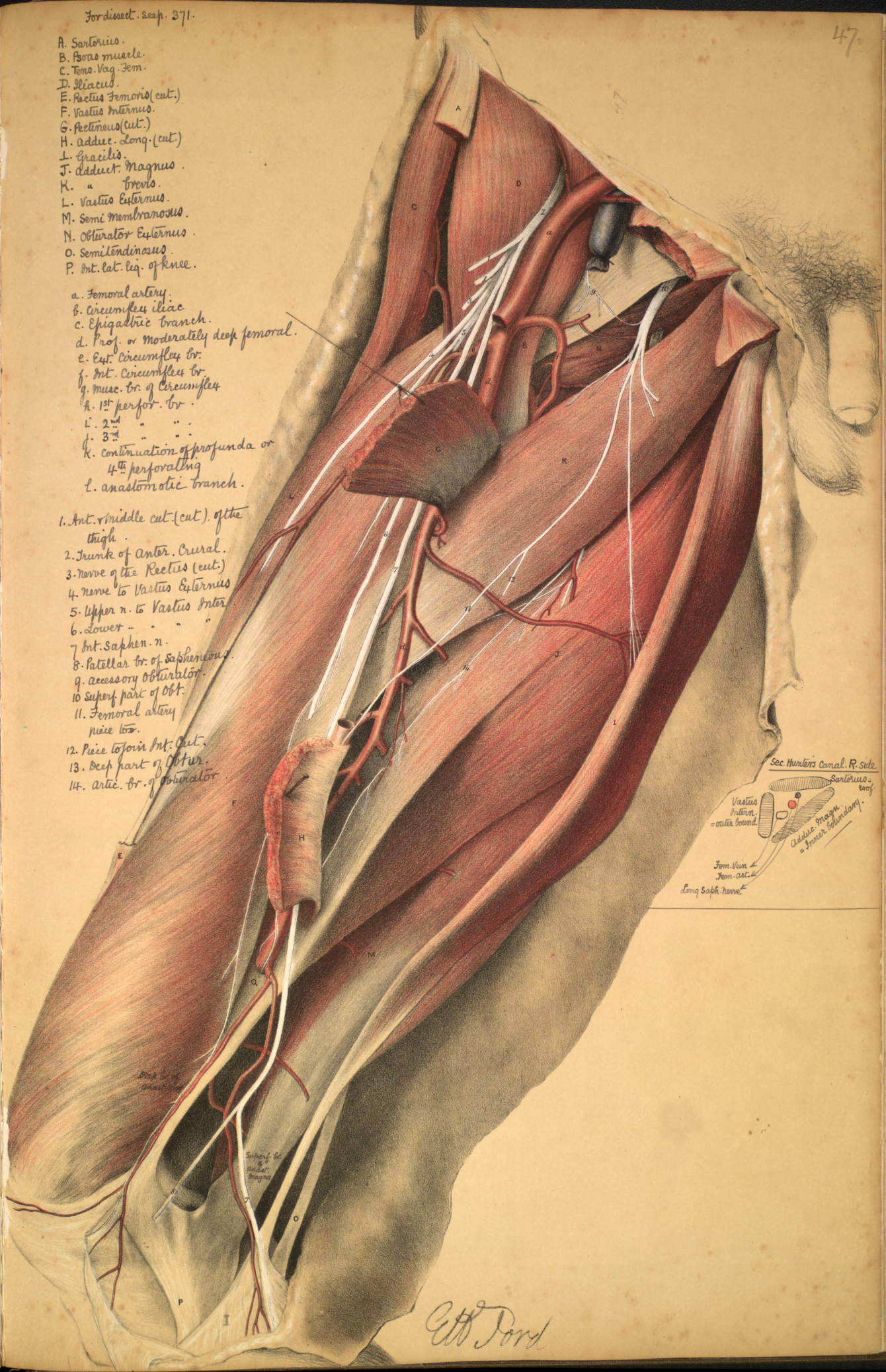

Ett Ford

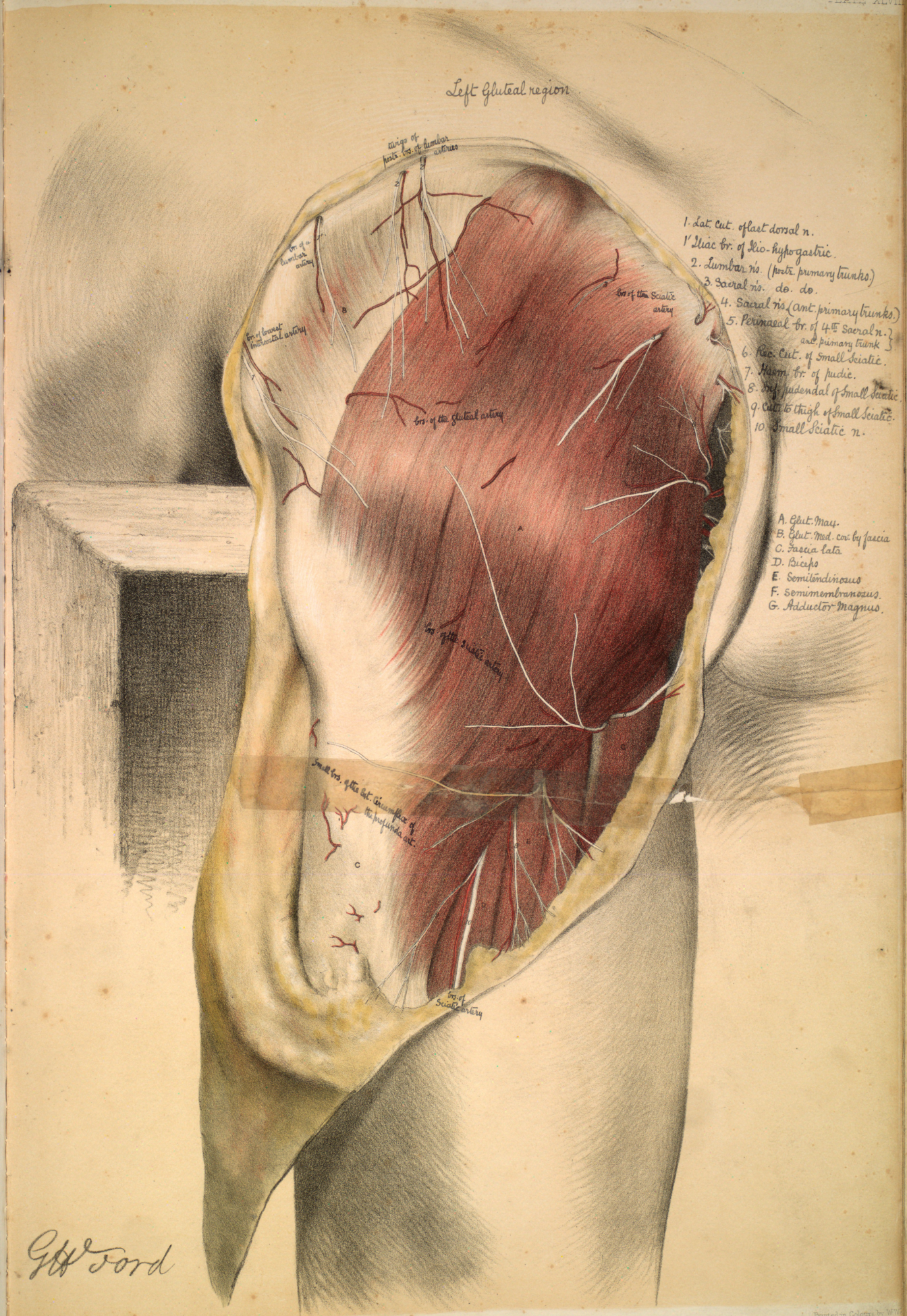

...n a dissection by G. V. Ellis.
London, Published November 1, 1866.
Printed in Colours by W. W...

Right Gluteal region

Second stage of the dissection of the Buttock. See p. 382.

2 groups of muscles (1) Abductors of Glutei (2) Ext. Rotators of Hip.

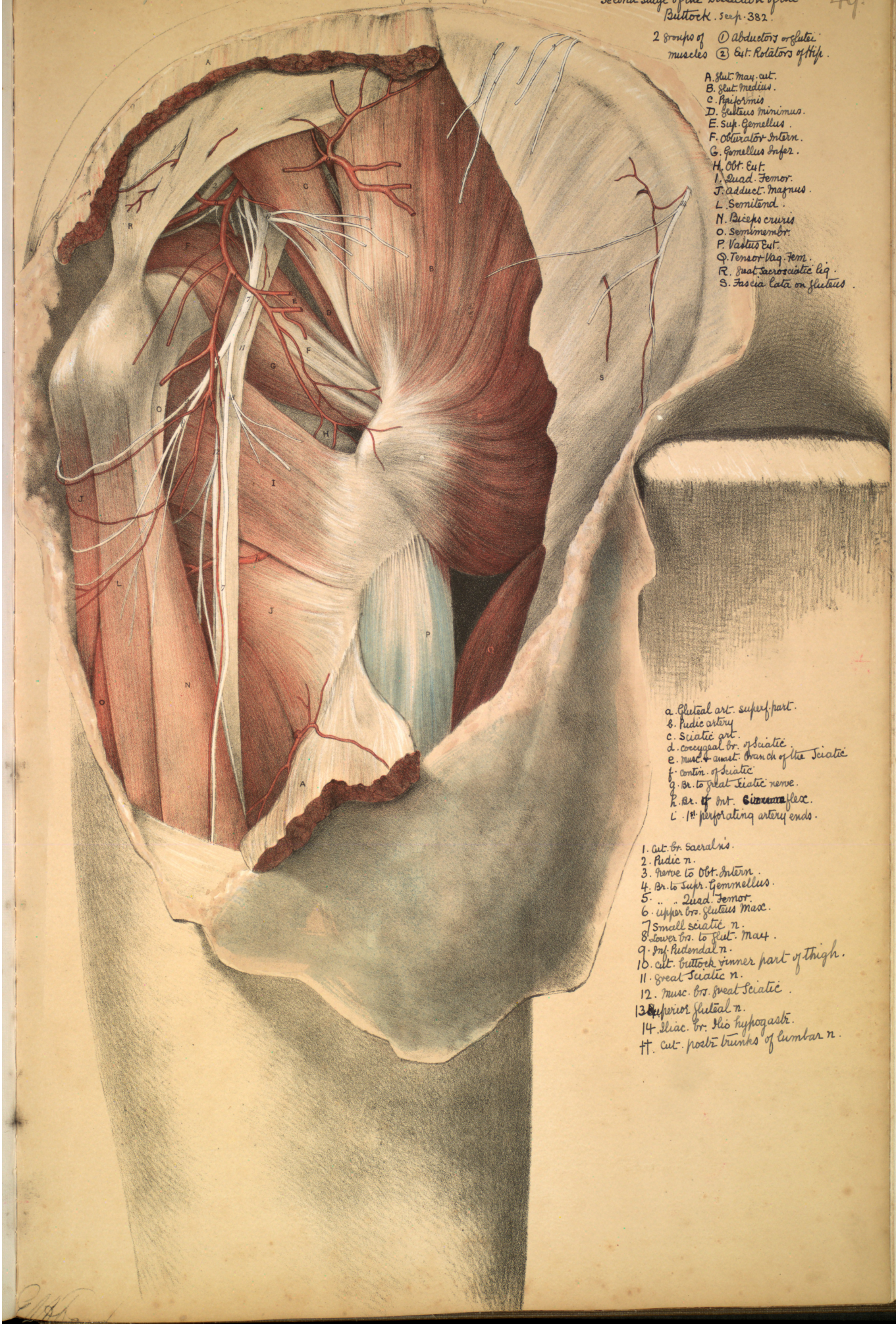

A. Glut. Max. cut.
B. Glut. Medius.
C. Piriformis
D. Gluteus minimus.
E. Sup. Gemellus.
F. Obturator Intern.
G. Gemellus Infer.
H. Obt. Ext.
I. Quad. Femor.
J. Adduct. Magnus.
L. Semitend.
N. Biceps cruris
O. Semimembr.
P. Vastus Ext.
Q. Tensor Vag. Fem.
R. Great Sacro-sciatic lig.
S. Fascia Lata on Gluteus.

a. Gluteal art. superf. part.
b. Pudic artery
c. Sciatic art.
d. coccygeal br. of Sciatic
e. musc. & anast. Branch of the Sciatic
f. contin. of Sciatic
g. Br. to great Sciatic nerve.
h. Br. of Int. Circumflex.
i. 1st perforating artery ends.

1. Cut. Br. Sacral n's.
2. Pudic n.
3. Nerve to Obt. Intern.
4. Br. to Supr. Gemmellus.
5. " " Quad. Femor.
6. upper brs. Gluteus Max.
7. Small sciatic n.
8. Lower brs. to Glut. Max.
9. Inf. Pudendal n.
10. Cut. Buttock inner part of thigh.
11. Great Sciatic n.
12. Musc. brs. Great Sciatic.
13. Superior Gluteal n.
14. Iliac. br. Ilio hypogastr.
15. Cut. poster trunks of Lumbar n.

3rd Stage in dissection of buttock. (A. 390)
(Right.)

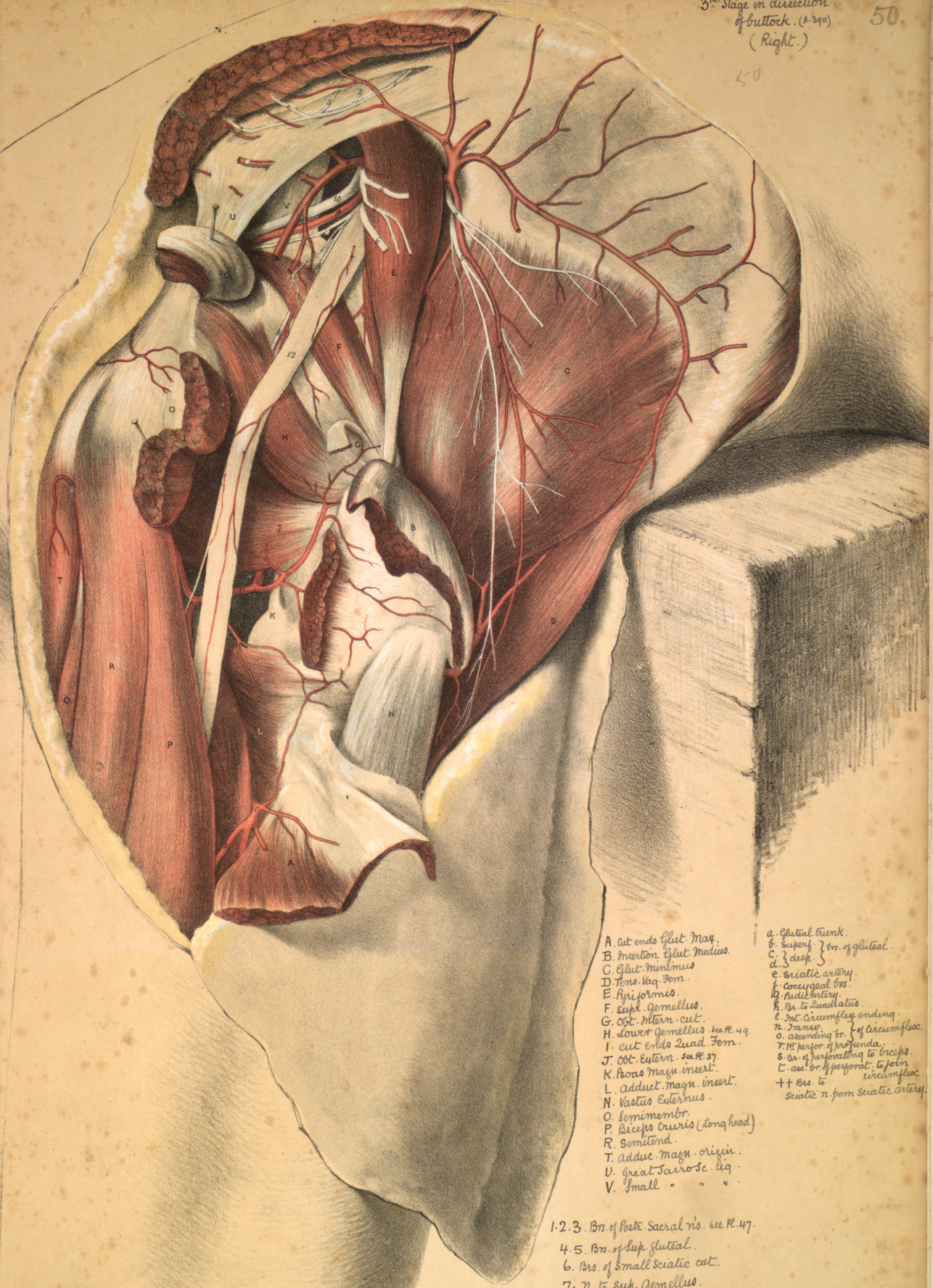

A. Cut ends Glut. Max.
B. Insertion Glut. Medius.
C. Glut. Minimus
D. Tens. Vag. Fem.
E. Pyriformis.
F. Sup. Gemellus.
G. Obt. Intern. cut.
H. Lower Gemellus. See Pl. 49.
I. cut ends Quad. Fem.
J. Obt. Extern. See Pl. 37.
K. Psoas Magn. insert.
L. Adduct. Magn. insert.
N. Vastus Externus.
O. Semimembr.
P. Biceps Cruris (long head)
R. Semitend.
T. Adduc. Magn. origin.
U. Great Sacro Sc. lig.
V. Small " " "

a. Gluteal trunk.
b. Superf. } Brs. of gluteal.
c. deep. }
d. Sciatic artery.
e. Coccygeal Brs.
f. Pudic artery.
g. Br. to Quadratus
h. Int. Circumflex ending.
i. Transv. } of Circumflex.
o. ascending Br. }
p. 1st perfor. of profunda.
s. Br. of perforating to Biceps.
t. asc. Br. of perforat. to join circumflex.
++ Brs. to Sciatic n. from Sciatic artery.

1.2.3. Brs. of Post. Sacral n's. See Pl. 47.
4.5. Brs. of Sup. Gluteal.
6. Brs. of Small Sciatic cut.
7. n. to Sup. Gemellus.
8. n. to Quad. Fem. See p. 397.
9. n. to Obt. Int.
10. Pudic n.
12. Great Sciatic n.
++ Cut Brs. of Sacral nerves.

Left.

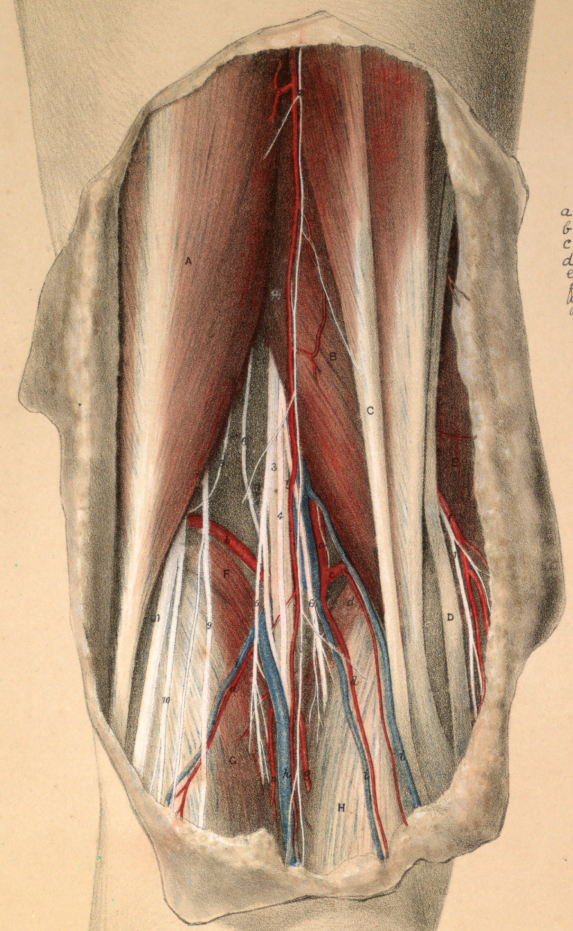

A. Biceps cruris.
B. Semi membr.
C. Semi tendin.
D. Gracilis.
E. Sartorius.
F. Plantaris.
G. Outer head } gastroc.
H. Inner head } gemius.

1. Int. Cut. n.
2. Small Sciatic.
3. Int. Pop. n.
4. Short Saph. n.
5. 6. Brs. to heads Gastroc.
7. Middle Artic. br.
8. Ext. artic. br.
9. Commun. Peroneal br.
10. Ext. Cut. leg.
11. Ext. Poplit. n.

a. Poplit. artery.
b. Upper Ext. artic.
c. Upper Int. artic.
d. Cut. brs. with Veins.
e. Cut. brs. + Small Sciatic.
f. Cut. br. of anastomotic.
g. Int. sural to gastroc n.
h. Short Saph. Vein.
i. Cut. veins back of leg.
k. Poplit. Vein.
n. Ext. Sural artery to gastroc.

E. A. Bord

Left leg.

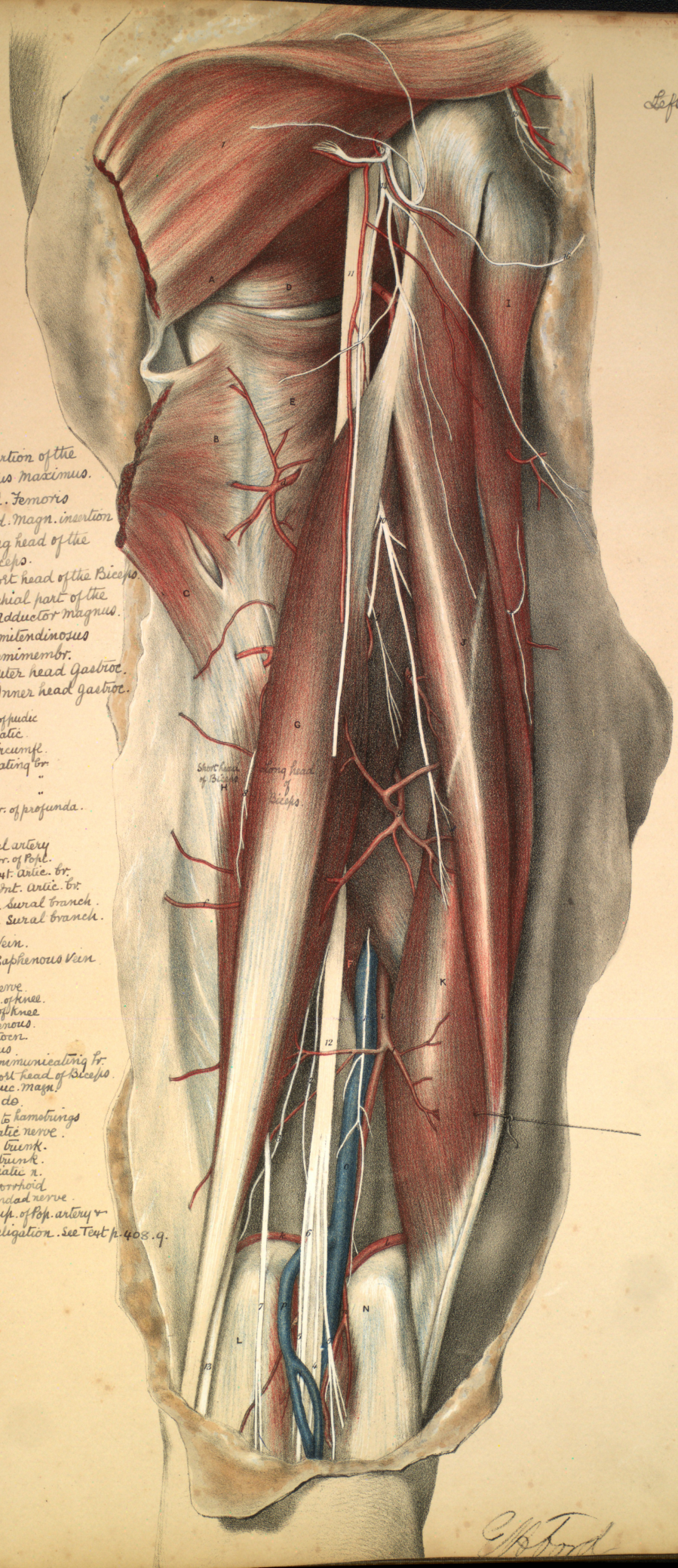

A B C. Insertion of the gluteus maximus.
D. Quad. Femoris
E F. Add. Magn. insertion
G. Long head of the Biceps.
H. Short head of the Biceps
I. Ischial part of the adductor magnus.
J. Semitendinosus
K. Semimembr.
L. Outer head Gastroc.
N. Inner head Gastroc.

a. Inf. haem. of pudic
b. Small Sciatic
c. Intern. Circumfl.
d. 1st perforating Br.
e. 2nd " "
f. 3rd " "
g. musc. br. of profunda.
h.
i. Popliteal artery
j. musc. br. of Popl.
K. Supr. Ext. artic. br.
l. Supr. Int. artic. br.
n. Inner Sural branch.
r. Outer Sural branch.

o. Poplit. Vein.
p. Short Saphenous Vein

1. Obturator nerve.
2. Br. to artic. of knee.
3. Ext. artic. of knee
4. Short Saphenous.
5. Brs. to gastrocn.
6. Br. to Soleus
7. Peroneal Communicating Br.
8. Nerve to Short head of Biceps.
9. Br. to adduc. magn.
+ a second do.
10. musc. br. to hamstrings
11. Great Sciatic nerve.
12. Int. Pop. trunk.
13. Ext. Pop. trunk.
14. Small sciatic n.
15. Inf. Haemorrhoid
16. Inf. Pudendal nerve.

For descrip. of Pop. artery & deligation. See Text p. 408. 9.

C. B. Ford

Right leg.

1. Inner br. Int. Cut. of thigh.
2. Int. or Long. Saphen. n.
3. Small Sciatic nerve.
4. Ext. or Short Saphenous n.
5. Peroneal commun. br. (Commun. fibularis)
6. Cut. br.
7. Inter. Poplit. nerve.
8. Extern. Poplit. nerve.

a. Pop. Art.
b. musc. br. of
c. Cut. br. with short Saph. n.
d. Cut. br. with Peroneal commun. n.
e. Cut. part of anastomotic artery
g. Pop. Vein
h. Int. or Long Saphen. vein.
i. Ext. or Short do. do.
f. Commun. br. between Saph. veins
K. Commun. to Saphen. from post. tibial v.

A. Biceps.
B. Semi Membr.
C. Semi Tend.
F. Inner head gastrocn.
G. Plantaris.
D. Sartorius.
H. Outer head gastrocn.
I. Plantaris tendon.
J. Soleus.
K. Tendo Achillis.

About 1 inch of Pop. art. is visible coming from beneath the Semi membranosus to disappear under the Inner head of the gastrocnemius.

2 inches Pop. Vein visible thus External (g.)
3 " Int. Pop. n. "
1 " Ext. Pop. n. "

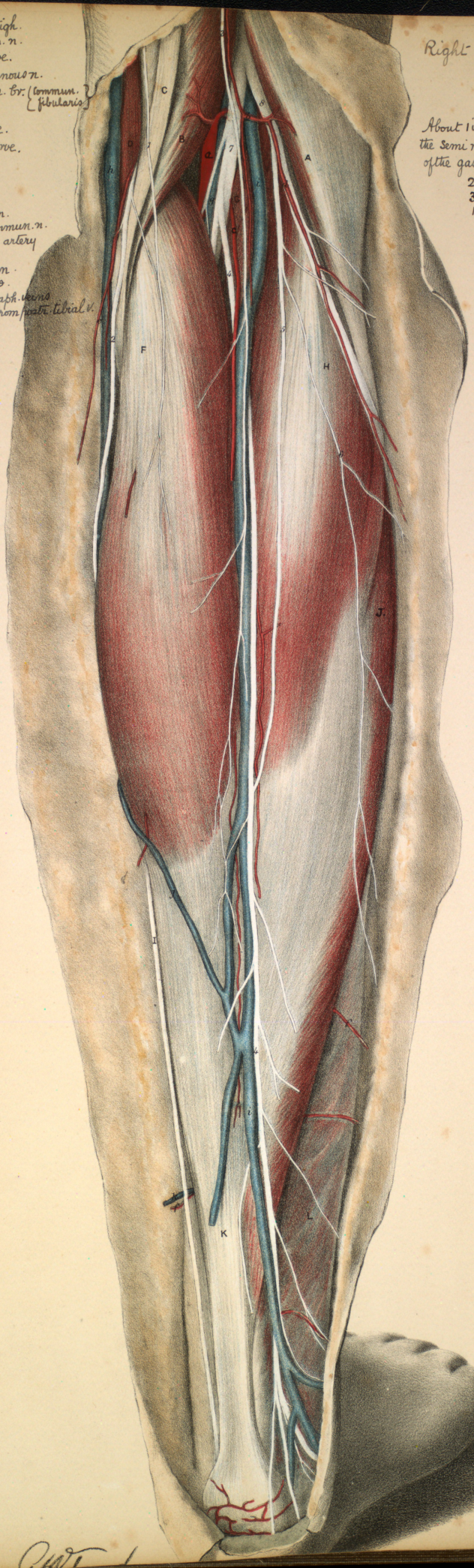

Deeper muscles of the Calf.
Soleus - Plantaris

Right leg.

A. Biceps cruris
B. Semi membranosus.
C. Semitendinosus
D. Sartorius
F. Inner head of Gastroc.
G. Plantaris
H. Outer head of Gastroc.
I. Popliteus.
J. Soleus.
K. Tendo Achillis.
X. Biceps
Z. Tendon of Semimembr. + Int. Condyle femur + Int. lat. lig.

a. Pop. artery.
b. upper muic. Br.
c. Br. to inner head of gastrocnemius.
d. Br. to outer " " " + plantaris
e. Inf. Ext. Artic.
f. Inf. Int. Artic.
g. Br. to Soleus
h. Pop. Vein
j. Int. Saph. Vein.
K. Ext. Saph. Vein.

1. Int. Pop. n.
2. Ext. Pop. n.
3. Br. to Inner head of Gastroc.
4. " " outer " " "
5. " " plantaris.
6. " " soleus
7. Inf. Int. Artic. nerve Br.
8. Origin Short Saph. n.
9. Br. to Popliteus.
10. Short. Saph. n. lower end.

Peroneal.

Right leg.

A. Popliteus.
B. Fibular origin } of the Soleus.
C. Tibial origin }
D. Flex. Long. Poll.
E. Flex. Long. digit.
F. Tib. Postic.
G. Tendo achillis, cut.
H. Peroneal muscles cov. by fascia.

a. Pop. art. trunk.
b. Inf. Ext. artic.
c. Inf. Int. artic.
d. Ant. Tibial trunk.
e. Peroneal trunk
f. Contin. of Peroneal.
g. Postr. Tibial trunk.

k. Pop. Vein.
l. Peroneal Venae comites
n. Postr. tibial do.
o. Commun. from deep to superf. veins.
p. Int. Saphenous vein.

1. Inf. Int. artic. n. 2. Int. Pop. 3. Br. to outer head gastroc.
4.5.6. musc. brs. of postr. tibial nerve.
4. to Tib. post.
5. to Flex. digit.
6. to Flex. Pollic.
7. a cutaneous plantar nerve. begins above os calcis. to sole. appears pierce Int. annular lig.
8. Int. Saphenous nerve.
9. Postr. tibial nerve.
10 Ext. Pop. n.

An aponeur. covering the central muscle is to be divided longitudinally & to be thrown inwards & outwards with fibres of the two lateral muscles attached to it.
In this group are 4 muscles 3 prolonged to the foot extend the ankle 4th crossing behind the knee flexes it.

5-5

Upper ½ of Postr. Tibial artery lies deeply
Lower ½ is superf.
Upper ½ Beneath Soleus resting on Tib. Post. (F.)
Int. is Flex. Long. Dig.
Ext. is Flex. Long. Poll. near termination.
Postr. Tib. n. trunk is Internal above
is External below origin of peroneal artery & remains so.
Ligature. Incis. 1 inch behind edge of tibia (behind Int. Saph. vein near edge of gastroc mem.)
(If too near edge of tibia to separate Soleus from bone you are apt to detach the deep flexor of the toes miss finding the interval between them & so get into a difficulty)
Turn aside the edge of the gastroen. cut through Soleus (extending ankle to relax muscle) & the aponeurosis on its under surface then the deep fascia under that & look externally for vessels.
The Postr. tibial n. onits outside is the guide.
Has a very thin sheath. On opening sheath be careful of the venae comites.

Lower ½ Postr. Tib. art.
Below middle leg the Soleus ends in its tendon artery lies between tendon & edge of tibia cov. by integ & deep fasc. on Flex. Long. dig. & end of tibia. outerside Flex. Long. Poll.

Ligature incise integum. with brs. of Int. Saph. vein & nerve but far enough back to clear trunk of vein. incise deep fascia. guide Postr. Tib. nerve.

Postr. tibial artery ends at lower end of Int. annular ligament.

bursa

In each limb
one main bloodvessel where there is one bone.
& 3 bloodvessels where there are two bones.

E.B. Ford

A. Abduct. poll.
B. Flex. Brev. dig.
C. Abduc. minimi dig.
E. Flexor tendon of great toe.
H. Lumbricales
K. Transv. lig. of the toes. (a deep trans. lig. connects heads of metatars. bones)
N. Flex. Brev. Poll.
O. Flex. min. dig.
P. Interossei of the outer space.

a. Cut. art. br. of sole.
b. Int. plantar trunk.
C. Ext. plantar trunk.
d. Dig. br. outside little toe.
e. " " inside great toe.
f. " " 1st + 2nd toes.
g. " " 2nd + 3rd toes.
h. " " 3rd + 4th " .
i. " " 4th + 5th " .

1. Cut. plantar n.
2. Int. " n.
3. Ext. " "
4. Dig. br. to great toe (inner side)
5. " " 1st + 2nd toes
6. " " 2nd + 3rd do.
7. " " 3rd + 4th toes.
8. Communicating of plantars.
9. Digit. of 4th + 5th
10. " outside of little toes

Fig I.
Superfic. vessels. ns. + 1st layer of muscles.

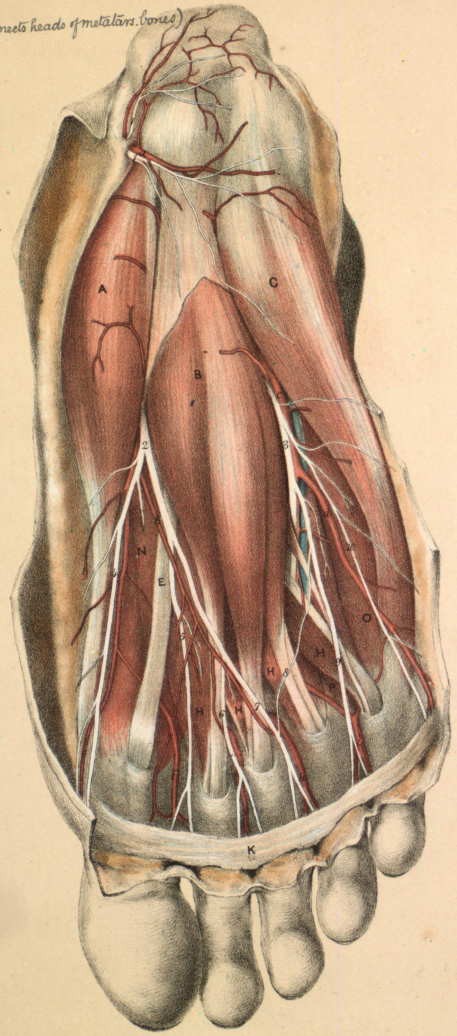

Fig II.
Second layer of muscles + the trunks of the plantar vessels + nerves.

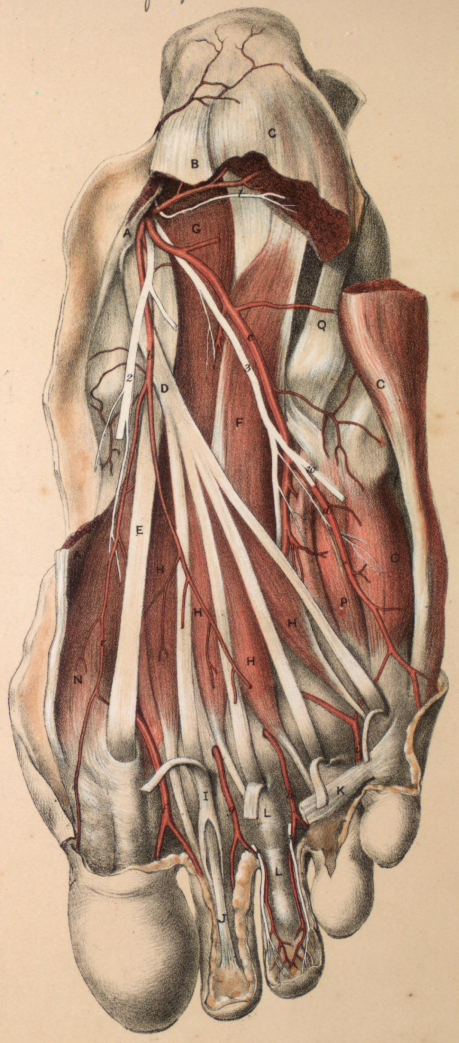

D. Flex. Long. digit.
E. Sheath of Flex. tendons D. Flex. Long. Poll.
F. Flex. accessorius.
G. Inner head of accessorius.
H. Lumbricales
I. Tendon of Flex. Brev. digit.
J. Tendon of Flex. Long. digit.
L. Sheath of Flex. tendons
N. Flex. Brev. Poll.
O. Flex. minimi digit.
P. Interossei.
Q. Tendon of Peron. Long.

E. H. Ford

57.

Take 2nd stage - divide the Accessorius muscle & the tendons of the flexors of the digits about 2 inches in front of the heel. Throw forwards the Flex. Perfor. with its lumbricales. Take care of the small nerves & arteries to the outer two lumbricales.

Fig. I. 3rd stage.
contg. Short muscles of the great and little toes

N. Flex. Brev. Poll.
O. Flex. Brev. Min. digit. (resembles the interossei)
Q. Peroneus Long.
R. Add. Poll.
S. Transv. Pedis. received across as short head of add. Poll.
T. Part of the tendon of the Tib. Postic.
U. Long plantar liq.

2. Int. Plant. n. cut
3. Ext. Plant. n.
4. Superf. or big. part of Ext. Plantar.
5. Deep part of Ext. Plant.
6. Br. to Transv. Pedis.
††. Branches to outer two lumbricales.

c Ext. Plantar Artery.
b. Int. Plantar Trunk.

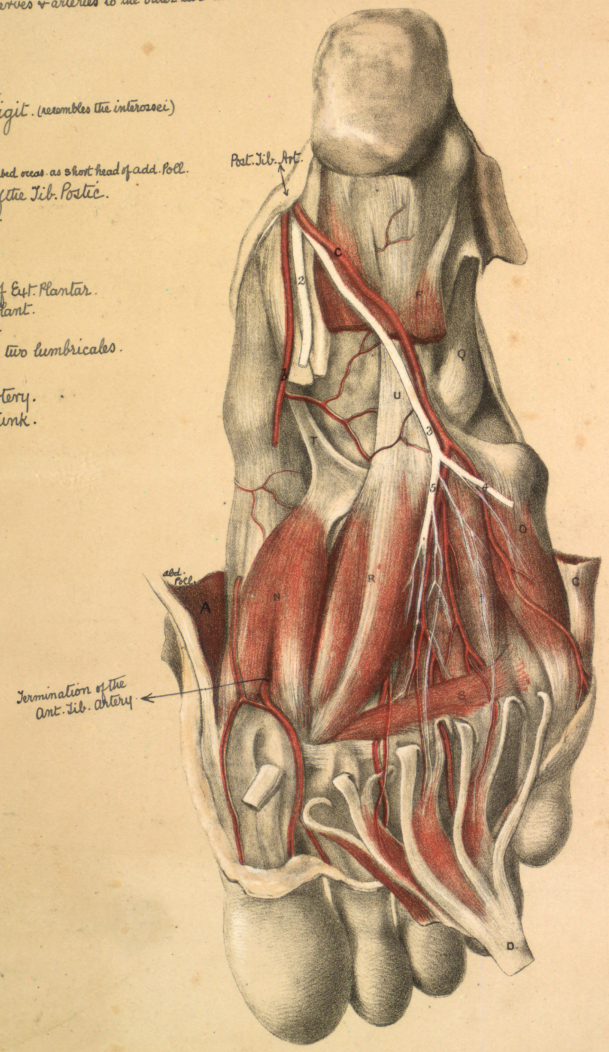

Fig II. 4th stage. Cut across & remove Add. & part of Flex. Brev. Poll. & lay bare the Plantar Arch. Remove the Trans. Pedis & the Trans. metat. liq. to define the three outer interossei.

M. V. W. Y. } prolongations of the tendon of Tib. Postic. at its insert.
X. Three plantar interossei
Z. Four dorsal interossei.
Q. Tendon of Peron. Long.
U. Long Plantar liq.
T. Inser. Tib. Post.

c. Ext. Plantar Art.
d. big. br. outside of little toe.
e. " " inside " great toe.
f. " " 1st & 2nd toes.
g. " " 2nd & 3rd toes.
h. " " 3rd & 4th " .
i. " " 4th & 5th " .
l. dorsal artery of foot.
n. Artery of the great toe. Art. magn. Poll.
o. commun. br. to deep arch.
s. poste. perfor. brs.

3. Ext. Plant. n.

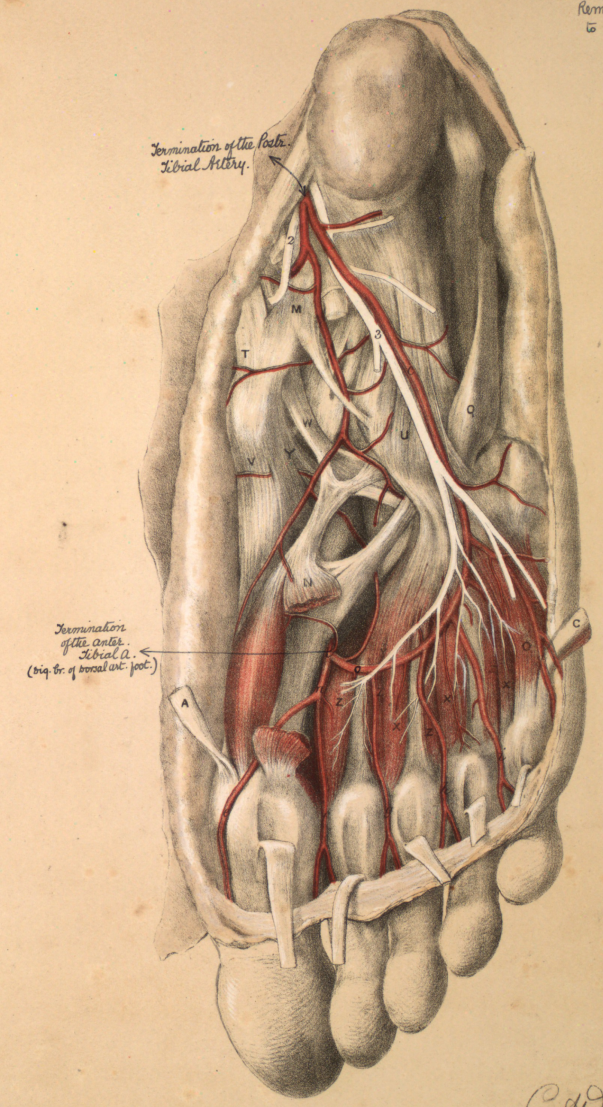

G. V. Ford

67.

From a dissection by G.V. Ellis.

London. Published Sept. 1, 1867.

Printed in Colours by W. West

Right leg.

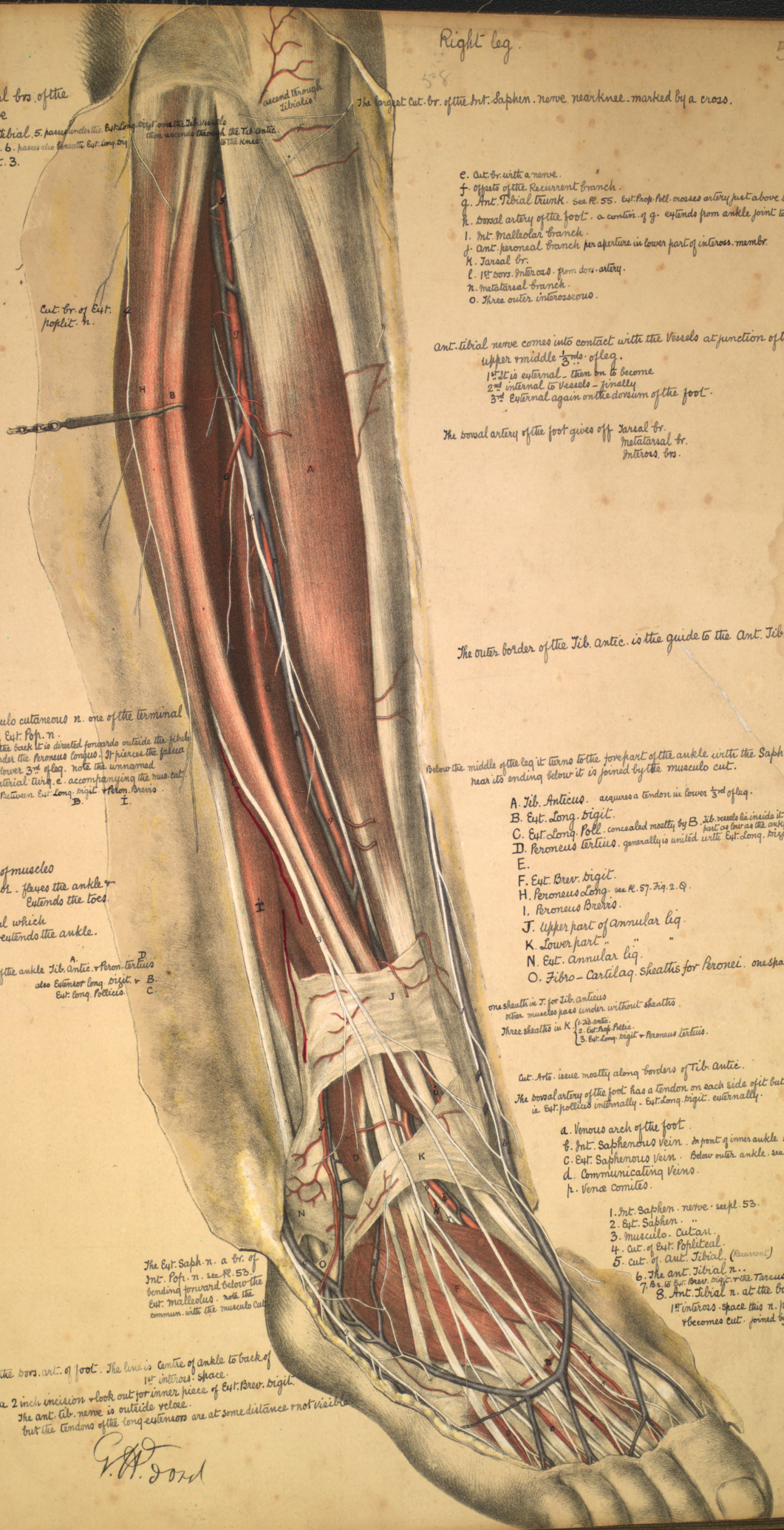

Three terminal brs. of the Ext. Pop. nerve
① Recurrent Tibial. 5. pass under the Ext. Long. digit. over the Tib. vessels then ascends through the Tib. antic.
② Ant. Tibial. 6. passes also beneath Ext. long. Dig
③ Musculo Cut. 3.

ascend through Tibialis

The longest Cut. br. of the Int. Saphen. nerve near knee. marked by a cross.

e. Cut. br. with a nerve.
f. Offsets of the Recurrent branch.
g. Ant. Tibial trunk. see Pl. 55. Ext. Prop. Poll. crosses artery just above the ankle.
h. Dorsal artery of the foot. a contin. of g. extends from ankle joint to entrance to sole.
i. Mt. Malleolar branch.
j. Ant. peroneal branch per aperture in lower part of inteross. membr.
K. Tarsal br.
l. 1st dors. Inteross. from dors. artery.
n. metatarsal branch.
o. Three outer interosseous.

Cut. br. of Ext. Poplit. n.

Ant. tibial nerve comes into contact with the Vessels at junction of the upper & middle 3rds. of leg.
1st it is external - then br. to become
2nd internal to Vessels - finally
3rd External again on the dorsum of the foot.

The dorsal artery of the foot gives off Tarsal br.
Metatarsal br.
Interos. brs.

The outer border of the Tib. antic. is the guide to the Ant. Tib. vessels.

The musculo cutaneous n. one of the terminal pieces of Ext. Pop. n.
from the back it is directed forwards outside the fibula under the peroneus longus. It pierces the fascia in lower 3rd of leg. note the unnamed arterial twig. e. accompanying the musc. cut.
Between Ext. Long. digit & Peron. Brevis.
B. I.

Below the middle of the leg it turns to the fore part of the ankle with the Saph. Vein. near its ending below it is joined by the musculo cut.

A. Tib. Anticus. acquires a tendon in lower 1/3rd of leg.
B. Ext. Long. digit.
C. Ext. Long. Poll. concealed mostly by B. Tib. vessels lie inside it for the most part as low as the ankle - then outside
D. Peroneus tertius. generally is united with Ext. Long. digit.
E.
F. Ext. Brev. digit.
H. Peroneus Long. see Pl. 57. Fig. 2. Q.
I. Peroneus Brevis.
J. Upper part of Annular lig.
K. Lower part " " "
N. Ext. annular lig.
O. Fibro-Cartilag. Sheaths for Peronei. one space for two peronei.

Two groups of muscles
an anterior. flexes the ankle & Extends the toes.
a lateral which extends the ankle.

Two flexors of the ankle Tib. Antic. (A) & Peron. tertius (D) also Extensor long. digit (B) & Ext. Long. Pollicis (C).

one sheath in J. for Tib. anticus
other muscles pass under without sheaths.
Three sheaths in K { 1. Tib. antic. 2. Ext. Prop. Pollic. 3. Ext. Long. digit & Peroneus tertius.

Cut. Arts. issue mostly along borders of Tib. Antic.
The dorsal artery of the foot has a tendon on each side of it but 1/2 inch from it. Ext. pollicis internally - Ext. Long. digit. externally.

a. Venous arch of the foot.
b. Int. Saphenous Vein. in front of inner ankle see Pl. 53.
c. Ext. Saphenous Vein. Below outer ankle. see Pl. 53.
d. Communicating Veins.
p. Venae comites.

1. Int. Saphen. nerve. see pl. 53.
2. Ext. Saphen. "
3. Musculo-Cutan.
4. Cut. of Ext. Popliteal.
5. cut. of Ant. Tibial. (Recurrent)
6. The ant. Tibial n...
7. Br. to Ext. Brev. digit. & Tarseus.
8. Ant. Tibial n. at the back of the 1st Interos. space this n. pierces fascia & becomes cut. joined by musculo-cut.

The Ext. Saph. n. a br. of Int. Pop. n. see Pl. 53. bending forward below the Ext. Malleolus. note the communi. with the musculo Cut.

To ligature the dors. art. of foot. The line is centre of ankle to back of 1st interos. space.
then a 2 inch incision & look out for inner piece of Ext. Brev. digit.
The ant. tib. nerve is outside & close.
but the tendons of the long extensors are at some distance & not visible.

F. H. Ford

A. Fascia of forearm.
B. Offset to fascia from tendon of Biceps.
C. Inner Intermusc. Septum.
D. Biceps.
F. Brachialis Anticus.
H. Coraco. brachialis muscle.
K. Inner head of Triceps.
M. Middle head of Triceps.
N. Teres Major.
P. Latiss. Dorsi.
R. Pectoralis Major.
S. Deltoid.

a. Median Vein.
b. b. Ant. Ulnar veins
c. Post. Ulnar Vein.
d. Median Cephalic Vein.
f. Median Basilic Vein.
g. Basilic Vein.
h. Cephalic Vein.
s. Inner Companion Vein of Brachial artery.

K. Brachial artery
* Spot best suited for ligature.
l. Ext. Mammary Br. or accessory.
m. Musc. offset of Supr. Profunda.
n. Infer. Profunda.
p. Anastomotic Branch.

1. Int. Cut. of Musculo Spiral
2. Br. of Musculo Sp. to Inner & Middle heads of Triceps. See Pl. 6. fig. 2. lies close to Ulnar n. until it enters musc. fibre.
3. Nerve of Wrisberg.
4. Intern. Cut. n.
5. Anter. Br. of Int. Cut. n.
6. Poster. do.
7. Median n.
8. Ulnar n.
9. Brs. of Cervical plexus.

For indications of paralysis of any of these nerves.
See Box & Eccles Clinical applied Anatomy p. 234 to 243.
an excellent account.
N.B.
also Eisendrath's Clin. Anat. p. 397 & 482.
" Butler's Medical diag. p. 1037.
" Taylor's applied Anatomy p. 332. Woolsey's do. & Schultze's atlas of applied anatomy.

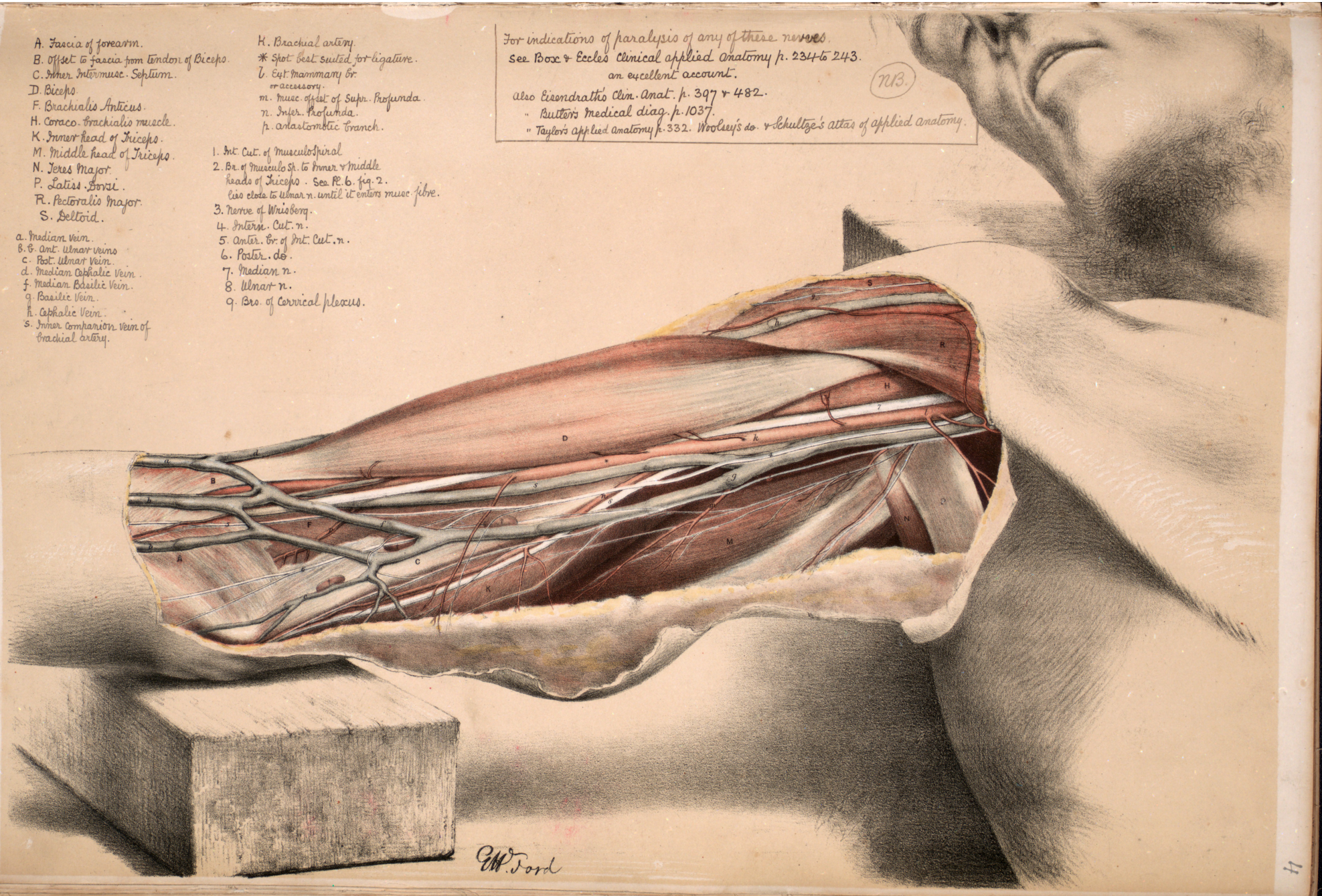

C.W. Ford